

Monaldi Archives for Chest Disease

eISSN 2532-5264 https://www.monaldi-archives.org/

Publisher's Disclaimer. E-publishing ahead of print is increasingly important for the rapid dissemination of science. The ***Early Access*** service lets users access peer-reviewed articles well before print / regular issue publication, significantly reducing the time it takes for critical findings to reach the research community.
These articles are searchable and citable by their DOI (Digital Object Identifier).

The **Monaldi Archives for Chest Disease** is, therefore, e-publishing PDF files of an early version of manuscripts that have undergone a regular peer review and have been accepted for publication, but have not been through the typesetting, pagination and proofreading processes, which may lead to differences between this version and the final one.
The final version of the manuscript will then appear in a regular issue of the journal.

E-publishing of this PDF file has been approved by the authors.

All legal disclaimers applicable to the journal apply to this production process as well.

Monaldi Arch Chest Dis 2026 [Online ahead of print]

To cite this Article:
Savio J, Padaki P, Ramachandran P, et al. **Diagnosis of chronic pulmonary aspergillosis in post-tuberculosis lung disease using an objective chest radiograph scoring**. *Monaldi Arch Chest Dis* doi: 10.4081/monaldi.2026.4042

Submitted: 13-04-2026
Accepted: 28-09-2026

©The Author(s), 2026
Licensee PAGEPress, Italy

Note: The publisher is not responsible for the content or functionality of any supporting information supplied by the authors. Any queries should be directed to the corresponding author for the article.
All claims expressed in this article are solely those of the authors and do not necessarily represent those of their affiliated organizations, or those of the publisher, the editors and the reviewers. Any product that may be evaluated in this article or claim that may be made by its manufacturer is not guaranteed or endorsed by the publisher.

Diagnosis of chronic pulmonary aspergillosis in post-tuberculosis lung disease using an objective chest radiograph scoring

Jayanthi Savio,[1] Priyadarshini Padaki,[1] Priya Ramachandran,[2] Chitra Veluthat,[2] Kavitha Venkatnarayan,[2] Uma Maheshwari,[2] Tinku Thomas,[3] Uma Devaraj[2]

[1]Department of Microbiology, St. John's National Academy of Health Sciences, Bangalore, Karnataka; [2]Department of Pulmonary Medicine, St. John's National Academy of Health Sciences, Bangalore, Karnataka; [3]Department of Biostatistics, St. John's National Academy of Health Sciences, Bangalore, Karnataka, India

Correspondence: Priya Ramachandran, Department of Pulmonary Medicine, St. John's National Academy of Health Sciences, Bangalore, Karnataka, India.
Tel.: 91-9663590386. E-mail: supriarvind@gmail.com

Contributions: all authors have contributed significantly and that all authors agree with the content of the manuscript. All the authors have read and approved the final version of the manuscript and agreed to be accountable for all aspects of the work. Priya Ramachandran: concept, patient recruitment, writing the manuscript, X-ray scoring. Jayanthi Savio, Priyadarshini Padaki: concept, analysis of lab samples, writing the manuscript, proof reading and approval. Chitra Veluthat, Kavitha Venkatnarayan, Uma Maheshwari, Uma Devaraj: concept, patient recruitment, proofreading.

Conflict of interest: the authors declare that there is no conflict of interest.

Ethics approval and consent to participate: the institutional Ethics Committee approved the study. Approval Number-220-2019.

Informed consent: Informed consent was obtained by the study team before data collection.

Patient consent for publication: all participants gave informed consent.

Availability of data and materials: the data used to support the findings of this study are available from the corresponding author upon request.

Funding: Rajiv Gandhi Health University of Sciences. Grant No-19MED 067

Declaration of generative artificial intelligence and artificial intelligence-assisted technologies in the writing process: non-generative AI was used. The text was scrutinized for grammatical errors and plagiarism by Grammarly.

Abstract

Chronic pulmonary aspergillosis (CPA) is an important but often overlooked complication of post-tuberculosis lung disease (PTLD), particularly in patients presenting with persistent respiratory symptoms after completion of anti-tuberculosis treatment (ATT). Data on its prevalence in resource-limited settings remains variable, and the diagnostic algorithm is not standardized. Hence, this study was undertaken with the objective of estimating the prevalence of CPA using a simplified diagnostic approach based on chest radiograph scoring. This cross-sectional study included sputum smear acid-fast bacilli-negative PTLD patients presenting with persistent respiratory symptoms for more than 3 months after completion of ATT. CPA was diagnosed using GAFFI criteria. The chest radiograph was scored for the percentage of lung affected plus 40 if cavitation was present. Of the 229 subjects evaluated, 91 (39.73%) were diagnosed with CPA based on serum *Aspergillus fumigatus*-specific IgG, symptoms, and chest radiography. These patients presented at a significantly younger age and had a shorter mean duration since completion of ATT. The presence of a cavity on a chest radiograph was a significant risk factor for CPA. Although the mean chest radiograph score was higher in CPA patients, the difference was not statistically significant. CPA among PTLD patients occurred between 2 and more than 10 years after successful completion of ATT. Chest radiography, especially with a cavity, combined with *A. fumigatus*-specific IgG testing, offers a practical and cost-effective strategy for CPA screening in resource-constrained settings.

Key words: post-TB lung disease, chronic pulmonary aspergillosis, chest X-ray scoring, *A. fumigatus* IgG.

Introduction

India contributes to one third of world's tuberculosis (TB) burden with pulmonary tuberculosis (PTB) prevalence of 295.9/100,000 population [1]. Despite a bacteriological cure of TB, it was estimated that there were 155 million survivors of TB in 2020, and at risk for possible post TB disability. Post-tuberculosis lung disease (PTLD) is a chronic respiratory abnormality, with or without symptoms, attributable at least in part to previous PTB [2]. One of the deadly manifestations of PTLD is chronic pulmonary aspergillosis (CPA), caused by the ubiquitous fungus, *Aspergillus*.

Even after successful PTB treatment, subjects with CPA present with life threatening massive haemoptysis and worsening structural lung damage. In a pooled analysis the overall mortality was 25% among patients with CPA in PTLD [3].

The global estimate of CPA prevalence after successful treatment of PTB based on 2005 TB data suggests that approximately 1.2 million people are affected [4]. The fact that the trajectory of CPA burden is increasing is evident from recent estimates of 3 million global cases of CPA [5]. More than 50% of subjects treated for PTB and declared cured but persistently symptomatic are diagnosed as CPA [6,7]. The occurrence of CPA in PTB varies during the course of PTB, from 4–20% in early PTB to 1–54% in post-PTB [7,8]. The geographical location is also a determining factor. A few studies from countries with high TB burden like India and Vietnam have shown prevalence to vary from 10% - 50% [9,10]. Nationwide or zone-specific data from India is not available.

CPA is a potentially treatable condition when diagnosed early. Current recommendation for diagnosis of CPA among symptomatic subjects in whom active PTB is ruled out includes chest radiology which is usually Computed Tomography of thorax, serum *Aspergillus* IgG and sputum microscopy and fungal culture for *Aspergillus*. Low index of suspicion is attributed to overlapping clinical features (chronic cough, hemoptysis, weight loss) and radiological findings (cavities, nodules, infiltrates) that mimic post-TB sequelae, reactivation TB, or other chronic lung diseases. Evolving diagnostic criteria and limited access to specialized tests, delays the diagnosis of CPA. Most centers prioritize management of TB but not PTLD, especially CPA.

The other issue is misdiagnosis of CPA as smear-negative PTB or bronchiectasis exacerbation and starting ATT/antibiotics adding to the problem of antimicrobial drug resistance [11]. There is an urgent need for a simple cost-effective diagnostic algorithm to quickly evaluate

symptomatic PTLD subjects especially in the TB follow-up centres to prevent morbidity and mortality.

This study was undertaken at our tertiary care centre in South India, a setting where patients with PTLD and associated complications are referred for further management to evaluate the occurrence of CPA among these subjects using a simple scoring of chest radiograph and serum *A.fumigatus* IgG.

Materials and Methods

This cross-sectional study was approved by the Institutional Ethics Committee and undertaken during the period January 2020 to December 2023.

Sample size calculation

Based on the study by Denning et al [4], sample size was calculated using a 22% prevalence rate of CPA in patients with PTB. With a 95% confidence level and 5% margin of error, sample size of approximately 264 was calculated.

Study population

Symptomatic subjects with a previous history of PTB treatment who were declared sputum smear-negative for acid-fast bacilli (AFB) by Ziehl–Neelsen (ZN) staining were included. The symptoms considered were persistent cough, weight loss or heamoptysis of more than 3 months duration. A detailed clinical history and systemic examination were carried out. Investigations included a chest radiograph and examination of an on-spot sputum sample for AFB using ZN stain. AFB smear negative subjects were included with an informed consent, and their serum samples were subjected to *A.fumigatus* IgG evaluation. Results of CT thorax where available were analysed. Serum *A. fumigatus* IgG was determined using the automated ImmunoCAP fluoro enzyme immune assay - (Phadia 100, Thermofisher Scientific, Waltham, MA) with >27 mgA/L as the recommended cut-off published for Indian population [12].

Chest radiograph scoring

The pulmonologist interpreted and scored the chest radiograph based on the extent of involvement as described by Anna Ralph et al [13,14]. A horizontal line was drawn half-way between two points on a line drawn from highest point where lung is seen (first rib) to the lowest point of diaphragm. Each quadrant thus obtained was viewed separately covering

adjacent sections with a card. The amount of normal and abnormal lung visualised was estimated for each quadrant and a score was applied – e.g. if half the area under review was abnormal, then a score of 50 was applied. An average across all quadrants was obtained for the whole x-ray. If cavity was present, an extra score of 40, so the maximum total score was 140.

Data analysis

Data was summarised as n(%) for categorical variables and mean ± SD or as median (quartile1, quartile3) based on the distribution of continuous variables. The normality assumption was examined using Q-Q plots. The Chi-square test, independent sample t-test or Mann-Whitney U test were used for comparison between categories. The comparisons after Bonferroni adjustment for multiple testing were considered significant with a p value <0.05. All analysis were performed using STATA version 16.0.

Clinical definitions

CPA: Subjects with symptoms for more than 3 months, chest radiograph showing cavitary infiltrates and/or a fungal ball and/or peri cavitary fibrosis or infiltrates or pleural thickening; and a positive *A.fumigatus* IgG assay result (>27 mgA/L) and excluding active pulmonary tuberculosis (sputum smear negative for acid fast bacilli) were considered as CPA [15].

Massive haemoptysis: If the volume of expectorated blood is life-threatening requiring transfusion, hospitalization, intubation, bronchial artery embolization or emergency surgery.

Results

Of the 250 symptomatic subjects, 229 were included and 21 sputum AFB positive were excluded. The mean age was 52.6±14.05 years and 155 (67.6%) were males. Mean number of years since completion of ATT was 10.25(±8.3) years. Time period from ATT completion to presentation at our centre varied from less than two years to more than 10 years. 47(20.5%) patients presented within 2 years, 37(16.1%) between 2 to 5 years and 80(34.9%) between 5 to 10 years.

The predominant presenting symptoms included cough in 214(95%) and haemoptysis in 128(55.8%). 51(22%) of them had massive haemoptysis.

Mean chest radiograph score was 42.6(±26.6). Unilateral shadows were seen in 198(79.5%). The findings included cavity in 90(39.3%) and fungal ball in 38(16.6%) (Figure 1).

Bronchiectasis was seen in 125(54.5%) and 59(25.7%) had pleural thickening (Figure 2). Bilateral fungal ball was seen in 5 subjects (Table 1).

Among the recruited subjects(n=229), results of CT thorax were available for 116 subjects. Of them, fungal ball was seen in 52 (44.4%) and cavity in 90 (77.5%). Chest radiography failed to identify cavities in 32 of 90 subjects (32.6%) in whom CT thorax demonstrated cavitary lesions.

Analysis of *A.fumigatus* IgG among the 229 subjects recruited showed that 91(39.73%) had > 27 mgA/L. Demography, symptoms, time to presentation since completion of ATT, chest radiography score and its findings were compared between the two groups with *A.fumigatus* IgG above and below the cut-off. The findings with statistical significance in the *A.fumigatus* IgG > 27 mgA/L group included shorter duration of the time from successful completion of ATT to current clinical presentation (mean years = 8.4+/-7) (Figure 3) and the presence of cavity (47%) on chest radiograph. Though the findings of massive haemoptysis, chest radiograph score and presence of fungal ball (55.2%) were higher in this group they were not statistically significant.

Discussion

The clinical profile of subjects presenting with respiratory symptoms after completing ATT was studied with an attempt to evaluate the occurrence of CPA using a simple scoring of chest radiograph and serum *A.fumigatus* IgG. Of the 229 symptomatic subjects, 91 (39.73%) had CPA. These patients presented about two years earlier than the IgG negative subjects. The presence of cavity on chest radiograph was a significant risk factor for CPA in PTLD. The reported prevalence of CPA world-wide ranges from 5.3 to 78%. This wide range could be due to determinants like variability in study population symptomatic versus asymptomatic. The underlying diseases predisposing to CPA include sarcoidosis, bronchiectasis, PTLD, COPD etc [16,17]. The diagnostic criteria for CPA is still evolving. Hence the difference in diagnostic criteria used impacts the prevalence of CPA. The IgG detection method used (Precipitin versus ELISA versus lateral flow) would also impact the interpretation of data. The prevalence of CPA varies with the time points at which studies were undertaken post PTB diagnosis and treatment [16,17]. Incidence recently calculated was 4.2 per 100-person years. Prevalence was quoted to be 10.5% in subjects with post-tubercular lung abnormality. Over the years the prevalence would be affected due to new colonization and dropouts due to mortality [10].

The most common risk factor for CPA is PTB. The others include COPD, sarcoidosis, ABPA, bronchiectasis, etc [2]. Even if PTLD is considered as the most common predisposing factor, differences in the prevalence of PTB, MDR TB, HIV TB coexistence, and the practice to treat smear negative TB limit the generalisability of prevalence data across the globe even within the PTLD group. In subjects with PTB, CPA prevalence has been studied at various time points ie. within 2 months of starting ATT to end of treatment and post treatment [18-21]. While some studies have looked at one to many years after treatment, others have just mentioned past history of PTB and not specified time periods since treatment [9,21-25]. Diverse subject inclusion criteria have been used like recruitment regardless of symptoms, and others only symptomatic. Some are only hospital based while others are mixed including subjects from both the community and those seeking hospital consultation. *Aspergillus* seroconversion can occur anytime following the diagnosis of PTB. Prevalence in active PTB through to end of treatment varies from 0-6% at commencement of ATT and 8 -10% at the end of therapy, with some resolving and some developing CPA de novo during TB therapy [18].

In our study, we included sputum AFB smear-negative symptomatic PTLD subjects. Our subjects were predominantly middle-aged males which is consistent with other studies [26]. The symptoms reported included cough followed by haemoptysis. Though greater number of CPA subjects presented with haemoptysis, the association was not significant. Some studies have reported significantly a greater number of CPA subjects presenting with haemoptysis [11,23]. It is by far the most alarming symptom that drives patients to seek medical attention, but chronic persistent cough often overlooked could also be an important symptom that needs to be elicited. It requires further evaluation as 95% of our subjects presented with cough. Massive haemoptysis was seen in a large proportion of subjects but there was no mortality. Successful bronchial artery embolization was performed for all of them.

The prevalence of CPA was 39.7%. This is comparable to the prevalence of 32% reported in a similar study from India that qualified radiological imaging as CT or chest radiograph [27]. Two recently published meta-analyses reported CPA prevalence, ranging from 23% to 48% [26,28]. This wide rage could be attributed to the differences in the studies included in the meta-analysis. These studies also included either CT or chest radiograph as radiological evidence. The population studied was from a tertiary care hospital which would not be the first point of contact for majority of the subjects. Hence this data cannot be extrapolated to the general TB population. Lack of formal guidelines for the screening of PTLD subjects results in a delay in the evaluation and diagnosis of CPA.

CT Thorax is the gold standard radiological investigation for diagnosis of CPA. It also helps to ascertain resolution or progression of changes in the follow-up period. CT is often unavailable in resource-limited settings and routine TB centers under the national program. Despite using only chest radiograph which can potentially miss cavities (32% in our study) and subtle fibrosis/pleural thickening (28% in our study), the prevalence of CPA in the current study was comparable to those using CT.

The extent of lung damage has been found to be an independent predictor of CPA [29]. To help better management of PTLD patients in settings with availability of limited diagnostic resources we assessed the extent of lung damage due to PTB using the simple scoring system developed by Anna Ralph et al in the context of active pulmonary tuberculosis [13]. Applying the scoring to post-TB fibrosis was attempted previously among PTLD subjects who presented with haemoptysis and a higher score of more than 70 was associated with CPA [14]. The score provides heavy weightage (score of 40) to the presence of cavities, as a predictor of TB outcome. However, as a simple way to grade extent of lung damage, it was thought to be reasonable to use the same score in all symptomatic PTLD.

While the process is subjective, and less accurate than reviewing a CT scan for instance, the score still was a useful measure. This score worked well with subjects who had haemoptysis to pick up chronic pulmonary aspergillosis [14]. But in our study the mean chest radiograph score was higher though not statistically significant in subjects with CPA.

The scoring system evaluates the extent lung damage and adds an additional score of 40 for presence of a cavity. A lacuna with the scoring system is, a score of only 40 is added irrespective of the size or the number of cavities. It also does not take into account the thickness of the cavity wall or presence of fungal ball. Hence few modifications with additional points to these features may add to the predictive ability of the scoring system for CPA. This would aid a health care worker in the periphery to evaluate subjects at risk for CPA.

Another scoring system by Baes etal looked into a similar kind of score in subjects with PTLD and found that it correlated with spirometry scores [30]. This score was not chosen as it did not add weightage to presence of cavity which is an important predisposing factor for CPA.

As early as 1970, cavity on chest radiograph was considered a risk factor for CPA, highlighting it is a conducive niche for *Aspergillus* colonization and subsequent pathogenic effects [31]. In our study a significantly a greater number of subjects (47%) had cavity among CPA on chest radiograph. Other authors also found presence of a cavity was more in subjects with CPA like in our subjects [14,17].

Ours was a cross-sectional study that evaluated *Aspergillus* IgG in symptomatic PTLD patients irrespective of the duration since the completion of ATT and found the mean duration since the time of completion of ATT to be significantly lower than non-CPA subjects at 8.4 years. Literature on this is conflicting. It is comparable to a retrospective study from Vietnam in which about 75% of subjects were treated for PTB more than 7years prior to presentation. Findings of prevalence of CPA in PTLD ranged from no association with time since PTB to a higher prevalence observed with longer time that elapsed after TB treatment [26,32,33]. Prospective long-term follow-up studies beyond five years for evaluating this are sparce [23].The prolonged interval between completion of ATT and seeking medical attention as in our subjects (78% presented after two years) emphasizes the chronic and delayed nature of PTLD - CPA. The prevalence captured at any given point may be underreporting the true prevalence as the 5-year mortality rate in some forms of CPA is as high as 50% [3]. This emphasizes the need for evaluation for CPA in all AFB smear negative symptomatic patients presenting at any time after a microbiological PTB cure.

The detection of IgG against *A. fumigatus* is the most crucial investigation in the diagnosis of CPA. The biological reference level for *A.fumigatus* IgG though extensively investigated, a universal consensus is yet to be published. This could vary based on ethnicity, geographic location, climate differences, and exposure frequency. Other factors like prior antifungal therapy, steroids(inhaled/systemic), diabetes, subtypes of CPA add to the variability [34]. Detection of IgG against species other than *A. fumigatus* is yet to be explored [35]. Country specific cut-offs need to be established. Studies from India have used a value >27 mgA/L for CPA diagnosis. Several commercially available detection platforms are available for its detection. Of them the immunochromatographic and ELISA methods are commonly used. Studies have shown that both the platforms are comparable. The ICT is a point of care test (POCT) that is technically simple and easy to interpret that can be easily incorporated in the diagnostic algorithm even in a peripheral centre [24]. Studies have also evaluated performance with different sample types such as whole blood, serum or plasma. In our study the IgG in the positive group ranged from 27.6 mgA/L to 210 mgA/L.

Ours is one of the studies in which chest radiograph was exclusively used to define the structural distortion and scored objectively for the extent of the damage. Despite this, the occurrence of CPA in PTLD was comparable to other studies. A peripheral centre can use chest radiograph to screen subjects for CPA and send only the blood sample to the reference labs for estimation of IgG or use point of care tests. This makes screening for CPA cost effective.

This study was done at a tertiary care centre where only symptomatic subjects were recruited and ours was not the first point of contact. It was not indented to look at treatment outcomes and sample size could not be reached. CT Thorax was not available in all subjects.

Conclusions

Chronic pulmonary aspergillosis (CPA) is a common and under-recognized cause of persistent respiratory symptoms in patients with post-tuberculosis lung disease (PTLD). In this study, symptoms alone did not help identify CPA in PTLD. Chest radiograph with a cavity and serum Aspergillus specific IgG helped diagnose CPA in nearly 40% of our symptomatic PTLD subjects. Simple, resource-appropriate tools like chest radiograph with objective scoring and *Aspergillus*-specific IgG testing would be effective in the diagnosis of CPA.

References

1. Sathiyamoorthy R, Kalaivani M, Aggarwal P, Gupta S. Prevalence of pulmonary tuberculosis in India: A systematic review and meta-analysis. Lung India 2020;37:45-52.
2. Allwood BW, Nightingale R, Agbota G, et al. Perspectives from the 2(nd) International Post-Tuberculosis Symposium: mobilising advocacy and research for improved outcomes. IJTLD Open 2024;1:111-23.
3. Sengupta A, Ray A, Upadhyay AD, et al. Mortality in chronic pulmonary aspergillosis: a systematic review and individual patient data meta-analysis. Lancet Infect Dis 2025;25:312-24.
4. Denning DW, Pleuvry A, Cole DC. Global burden of chronic pulmonary aspergillosis as a sequel to pulmonary tuberculosis. Bull World Health Organ 2011;89:864-72.
5. Bongomin F, Gago S, Oladele RO, Denning DW. Global and multi-national prevalence of fungal diseases-estimate precision. J Fungi 2017;3:57.
6. Byrne A, Al-Hindawi Y, Plit M, et al. The prevalence and pattern of post tuberculosis lung disease including pulmonary hypertension from an Australian TB service; a single-centre, retrospective cohort study. BMC Pulm Med 2025;25:84.
7. Bongomin F. Post-tuberculosis chronic pulmonary aspergillosis: An emerging public health concern. PLoS Pathog 2020;16:e1008742.
8. Denning DW, Page ID, Chakaya J, et al. Case definition of chronic pulmonary aspergillosis in resource-constrained settings. Emerg Infect Dis 2018;24:e171312.

9. Nguyen NTB, Le Ngoc H, Nguyen NV, et al. Chronic pulmonary aspergillosis situation among post tuberculosis patients in vietnam: an observational study. J Fungi 2021;7:532.
10. Soundappan K, Sehgal IS, Prabhakar N, et al. Incidence and prevalence of chronic pulmonary aspergillosis in patients with post-tuberculosis lung abnormality: results from a community survey in North India. Mycoses 2024;67:e13711.
11. Ocansey BK, Otoo B, Adjei A, et al. Chronic pulmonary aspergillosis is common among patients with presumed tuberculosis relapse in Ghana. Med Mycol 2022;60:myac063.
12. Denning DW, Cadranel J, Beigelman-Aubry C, et al. Chronic pulmonary aspergillosis: rationale and clinical guidelines for diagnosis and management. Eur Respir J 2015;47:45-68.
13. Ralph AP, Ardian M, Wiguna A, et al. A simple, valid, numerical score for grading chest x-ray severity in adult smear-positive pulmonary tuberculosis. Thorax 2010;65:863-9.
14. Ramachandran P, Savio J, Padaki P, et al. A simple x-ray scoring system for the diagnosis of chronic pulmonary aspergillosis. Mycoses 2021;64:788-93.
15. GAFFI. TB and its sequela chronic pulmonary aspergillosis (CPA). Available from: https://gaffi.org/wp-content/uploads/Briefing-note-TB-and-CPA-August-2019.pdf.
16. Smith NL, Denning DW. Underlying conditions in chronic pulmonary aspergillosis including simple aspergilloma. Eur Respir J 2011;37:865-72.
17. Uzunhan Y, Nunes H, Jeny F, et al. Chronic pulmonary aspergillosis complicating sarcoidosis. Eur Respir J 2017;49:1602396.
18. Setianingrum F, Rozaliyani A, Adawiyah R, et al. A prospective longitudinal study of chronic pulmonary aspergillosis in pulmonary tuberculosis in Indonesia (APICAL). Thorax 2022;77:821-8.
19. Hedayati MT, Azimi Y, Droudinia A, et al. Prevalence of chronic pulmonary aspergillosis in patients with tuberculosis from Iran. Eur J Clin Microbiol Infect Dis 2015;34:1759-65.
20. Jha D, Kumar U, Meena VP, et al. Chronic pulmonary aspergillosis incidence in newly detected pulmonary tuberculosis cases during follow-up. Mycoses 2024;67:e13747.
21. Ocansey BK, Otoo B, Gbadamosi H, et al. Importance of aspergillus-specific antibody screening for diagnosis of chronic pulmonary aspergillosis after tuberculosis treatment: a prospective follow-up study in Ghana. J Fungi 2022;9:26.
22. Chirumamilla NK, Arora K, Kaur M, et al. Innate and adaptive immune responses in subjects with CPA secondary to post-pulmonary tuberculosis lung abnormalities. Mycoses 2024;67:e13746.

23. Page ID, Byanyima R, Hosmane S, et al. Chronic pulmonary aspergillosis commonly complicates treated pulmonary tuberculosis with residual cavitation. Eur Respir J 2019;53:1801184.
24. Sehgal IS, Soundappan K, Muthu V, et al. Performance of LDBio aspergillus ICT IgM/IgG lateral flow assay in diagnosing chronic pulmonary aspergillosis in community versus hospital setting. Mycopathologia 2025;190:9.
25. Singla R, Singhal R, Rathore R, et al. Risk factors for chronic pulmonary aspergillosis in post-TB patients. Int J Tuberc Lung Dis 2021;25:324-6.
26. Madden A, Ofori SK, Budu M, et al. A systematic review of chronic pulmonary aspergillosis among patients treated for pulmonary tuberculosis. Clin Infect Dis 2025;81:e163-71.
27. Selvasekhar A, Nath R, Gogoi G, Borah P. Chronic pulmonary aspergillosis in tea population of Assam. PLoS Negl Trop Dis 2025;19:e0012756.
28. Sehgal IS, Soundappan K, Agarwal R, et al. Prevalence of chronic pulmonary aspergillosis in patients with mycobacterial and non-mycobacterial tuberculosis infection of the lung: a systematic review and meta-analysis. Mycoses 2025;68:e70060.
29. Singhal R, Gupta A, Singla N, et al. Chronic pulmonary aspergillosis in a tertiary tuberculosis institute: a common entity missed commonly. Indian J Tuberc 2023;70:276-85.
30. Báez-Saldaña R, López-Arteaga Y, Bizarrón-Muro A, et al. A novel scoring system to measure radiographic abnormalities and related spirometric values in cured pulmonary tuberculosis. PLoS One 2013;8:e78926.
31. Davis D. Aspergilloma and residual tuberculous cavities--the results of a resurvey. Tubercle 1970;51:227-45.
32. Volpe-Chaves CE, Venturini J, B Castilho S, et al. Prevalence of chronic pulmonary aspergillosis regarding time of tuberculosis diagnosis in Brazil. Mycoses 2022;65:715-23.
33. Oladele RO, Gbajabimiala T, Irurhe N, et al. Prospective evaluation of positivity rates of aspergillus-specific IgG and quality of life in HIV-negative tuberculosis patients in Lagos, Nigeria. Front Cell Infect Microbiol 2022;12:790134.
34. Hsiao CW, Yen TH, Wu YC, et al. Comparison of Aspergillus-specific antibody cut-offs for the diagnosis of aspergillosis. Front Microbiol 2022;13:1060727.
35. White PL. Developments in fungal serology. Curr Fungal Infect Rep 2023;1-12.

Table 1. Baseline characteristics, symptoms and chest radiograph findings in the study subjects.

	Total (n=229)	*A.fumigatus* IgG≤27 mgA/L n=138 (60.26%)	*A.fumigatus* IgG>27 mgA/L n=91(39.73%)	p-value
Age (mean±SD)	52.6±14.0	54.0±14.5	50.5±13.2	0.067
Gender: Male	155(67.7)	92(77)	64(70)	0.598
Gender: Female	74(32.3)	46(33)	27(30)	
Mean duration since ATT in years	10.25(±8.3)	11.4±8	8.4(±7)	0.008
>2 yrs	184(80%)	113(82)	71(78)	0.472
Symptoms				
Haemoptysis +	128(55.8)	80 (58)	48(53)	0.947
Fever +	71(31)	41 (30)	31(34)	0.758
Dyspnoea +	98(42.7)	60 (43)	38 (42)	0.609
Chest radiograph				
Score (mean±SD)	42.6(±26.6).	40.4±26.2	45.9±27.1	0.939
Cavity +	90(39.3)	47(34)	43(47)	0.007
Pleural Thickening +	59(25.7)	36(26)	23(25)	0.983
Fungal ball +	38(16.5)	17(12.3)	21(23)	0.08

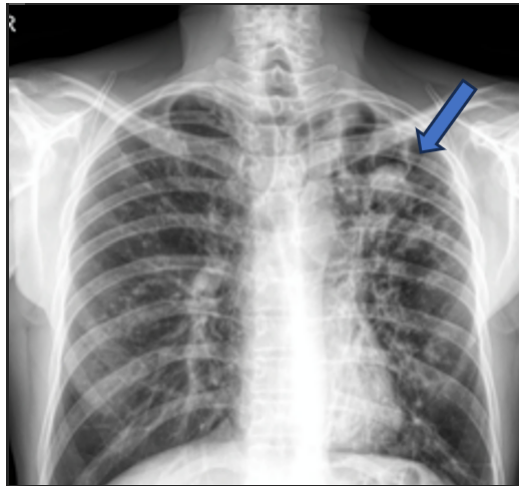

Figure 1. Chest radiograph showing a fungal ball inside a cavity in the left upper lobe in a subject who had *A.fumigatus* IgG 32mgA/L.

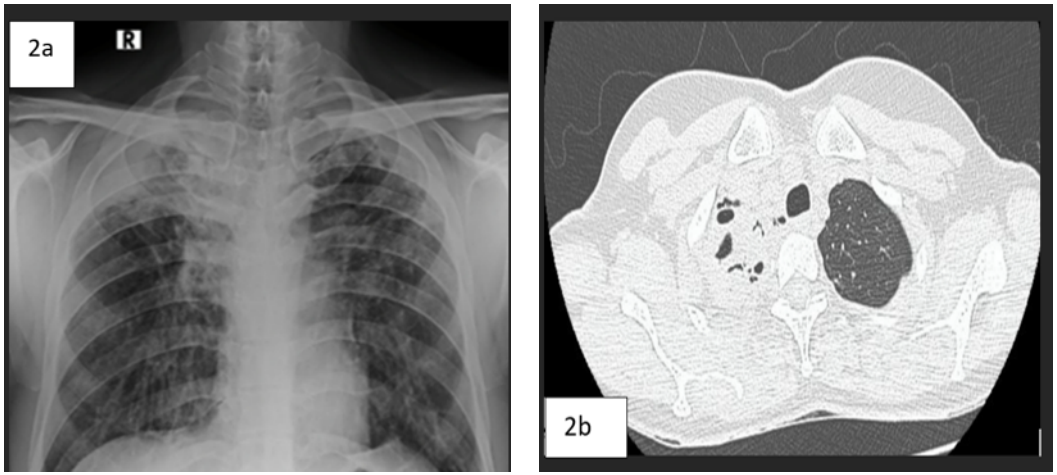

Figure 2. a) Chest Radiograph showing right upper lobe pleural thickening with bronchiectasis; b) CT Thorax of the same patient showing right upper lobe fibrosis with cavities.

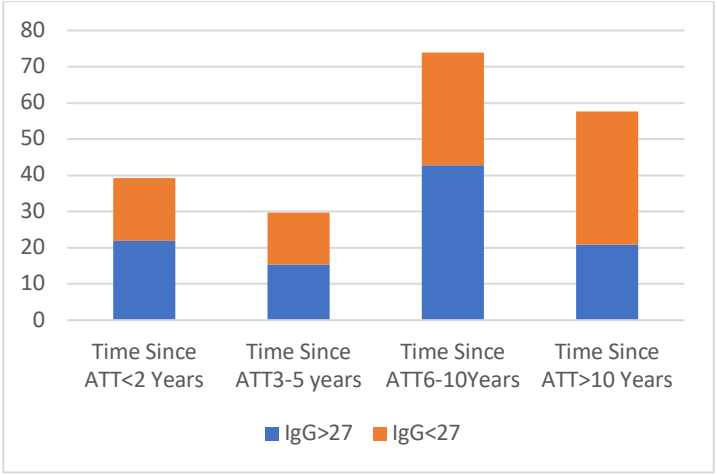

Figure 3. Graph showing correlation between time since Anti tubercular treatment and *A. fumigatus* IgG positivity.