

©Copyright: the Author(s), 2025
Licensee PAGEPress, Italy

Virtual bronchoscopic navigation and guided radial endobronchial ultrasound for peripheral pulmonary lesions: harmonizing modalities to optimize accuracy

Parul Mrigpuri, Sidharth Raj Yadav, Divyendu Sharma, Sonam Spalgais, Vidushi Rathi, Nitin Goel, Balakrishnan Menon, Raj Kumar

Department of Pulmonary Medicine, Vallabhbhai Patel Chest Institute, University of Delhi, New Delhi, India

Abstract

Peripheral pulmonary lesions (PPLs) present a significant diagnostic challenge due to their location beyond the reach of traditional bronchoscopy. With lung cancer being the leading cause of cancer-related mortality worldwide, accurate and early diagnosis of PPLs is crucial. Virtual bronchoscopic navigation (VBN) combined with radial endobronchial ultrasound (R-EBUS) has emerged as a promising technique to enhance the diagnostic yield for these lesions. This retrospective observational study evaluated the diagnostic yield of VBN-guided R-EBUS in patients with PPLs identified on computed tomography. The study included nine patients who underwent VBN-guided R-EBUS biopsy sampling. Patient demographics, lesion characteristics, and procedural outcomes were analyzed using descriptive and inferential statistics. The mean age of the patients was 57.33 years, with a mean lesion size of 3.24 cm. The diagnostic yield of VBN-guided R-EBUS was 77.7% (95% confidence interval: 68.5-85.8%). Non-small cell carcinoma was the most frequent histopathological diagnosis (55.5%). Complications included bleeding in two patients (22.2%) and bronchospasm in one patient (11.1%), all managed conservatively. VBN-guided R-EBUS provides high diagnostic accuracy and a low risk of complications in patients with PPLs.

Key words: peripheral pulmonary lesion, radial endobronchial ultrasound, virtual bronchoscopic navigation.

Correspondence to: Parul Mrigpuri, Department of Pulmonary Medicine, Vallabhbhai Patel Chest Institute, University of Delhi, New Delhi, 110007, India. Tel.: 8826687316. E-mail: parul57_mrigrigpuri@yahoo.com

Introduction

Lung lesions have been traditionally divided into central and peripheral lesions using either traditional methods involving chest X-rays or newer modalities like computed tomography (CT) and virtual bronchoscopic navigation (VBN) software. Peripheral pulmonary lesions (PPLs) are typically beyond the reach of traditional bronchoscopy [1,2]. These lesions pose a diagnostic challenge and are crucial due to their association with lung cancer, which remains the leading cause of cancer-related mortality worldwide [3]. Cancer incidence and mortality produced by the International Agency for Research on Cancer show that lung cancer remains the leading cause of cancer death, with an estimated 1.8 million deaths in 2020 [4]. The overall estimated lung cancer mortality in India is 5.9% of all cancer cases, making it the fourth most common cause of cancer-related mortality [5]. Lung cancer screening programs and chest CT scans have enabled the identification of asymptomatic peripheral lung nodules, highlighting the importance of early detection and accurate diagnosis. Differentiation between benign and malignant lesions can be done based on additional characteristics of lesions, including size, borders, calcification pattern, and enhancement features on CT [3]. Traditionally, transthoracic needle aspiration and surgical biopsy are more commonly used for the diagnosis of

peripheral lesions [6]. Newer bronchoscopic methods have emerged to be safer and with fewer complications, although the yield is variable [7]. Advancements in navigational bronchoscopy techniques, including VBN when combined with radial endobronchial ultrasound (R-EBUS) guided sampling using an ultrathin bronchoscope, have revolutionized the diagnostic approach to PPLs [2]. R-EBUS involves a flexible catheter housing a rotating ultrasound transducer that produces a 360° ultrasound image in real-time, aiding in the identification of lesions and sampling sites [8]. A recent meta-analysis found the pooled sensitivity of R-EBUS for detecting lung cancer in PPLs was up to the tune of 72%. However, significant heterogeneity was observed among the studies [9].

Some lesions remain unreachable with the radial probe because the R-EBUS system lacks a navigation device. This limitation can hinder the diagnostic process for certain PPLs, emphasizing the potential benefits of integrating R-EBUS with VBN or other navigational aids to enhance reach and accuracy [10,11]. VBN is an image-based technology that utilizes spatial information derived from CT images to guide a bronchoscope to PPLs [12]. When combined with R-EBUS, VBN can enhance the diagnostic yield for small PPLs. Previously done studies have shown varied results in terms of diagnostic yield [13,14]. A meta-analysis evaluating the efficacy and safety of transbronchial lung biopsy (TBLB) using R-



EBUS and VBN compared to CT-guided transthoracic needle biopsy for diagnosing small pulmonary lesions showed a higher diagnostic yield for the latter but with a higher complication rate [15].

This study aimed to assess the diagnostic yield of VBN-guided R-EBUS in sampling PPLs. By leveraging the synergistic potential of VBN and R-EBUS, this research seeks to offer insights into optimizing diagnostic strategies for early-stage lung cancer, ultimately contributing to the advancement of minimally invasive diagnostic techniques in pulmonology.

Materials and Methods

This was a retrospective observational study that took into account all patients diagnosed with a PPL on CT chest and underwent VBN-assisted R-EBUS-guided biopsy sampling in our institute over a period of 1 year. PPL was defined as a lung nodule measuring ≤ 3.5 cm in diameter and located in the lung periphery [16].

The files of all registered patients with investigations, clinical details, and other relevant data with diagnosis on file are kept in record in our hospital as an institute protocol. As the study involved secondary data analysis of data obtained using record review, ethics approval was not sought. The data collected did not have any identifiers, and confidentiality was ensured. The pre-procedure investi-

gations included complete hemogram, liver and kidney function tests, prothrombin time, bleeding time, clotting time, viral markers, electrocardiography, X-ray, and CT chest.

Specific lesion characteristics, which included size (short and long axis in mm), location (lobe and segment) within the lung field, number, borders (smooth, lobulated, spiculated, or irregular margins, pattern of calcification (diffuse, central, laminated, popcorn, eccentric), presence of involved bronchi and enhancement (mean Hounsfield unit) were recorded.

VBN technique utilizes data of helical CT to construct three-dimensional virtual images of the bronchial route to guide the bronchoscope to the target lesion [12]. We used the Lung Point navigation system (Broncus Medical Inc., Mountain View, CA, USA). The process involved two phases: i) planning phase – patient data from the CT was imported into the system *via* VBN software, which then reconstructed a 3D structure of the bronchial tree with the lesion localised and the pathway to it; ii) procedure phase – in this phase, the lesion was reached based on the pathway determined in the planning phase. For this, a bronchoscope with the assistance of R-EBUS was used, followed by biopsy.

The procedure involved the use of R-EBUS (Olympus Corporation, Tokyo, Japan) with Ultrathin Bronchoscope (Olympus Corporation, Tokyo, Japan) and Adult Bronchoscope (Olympus Corporation, Tokyo, Japan) and was done under conscious sedation

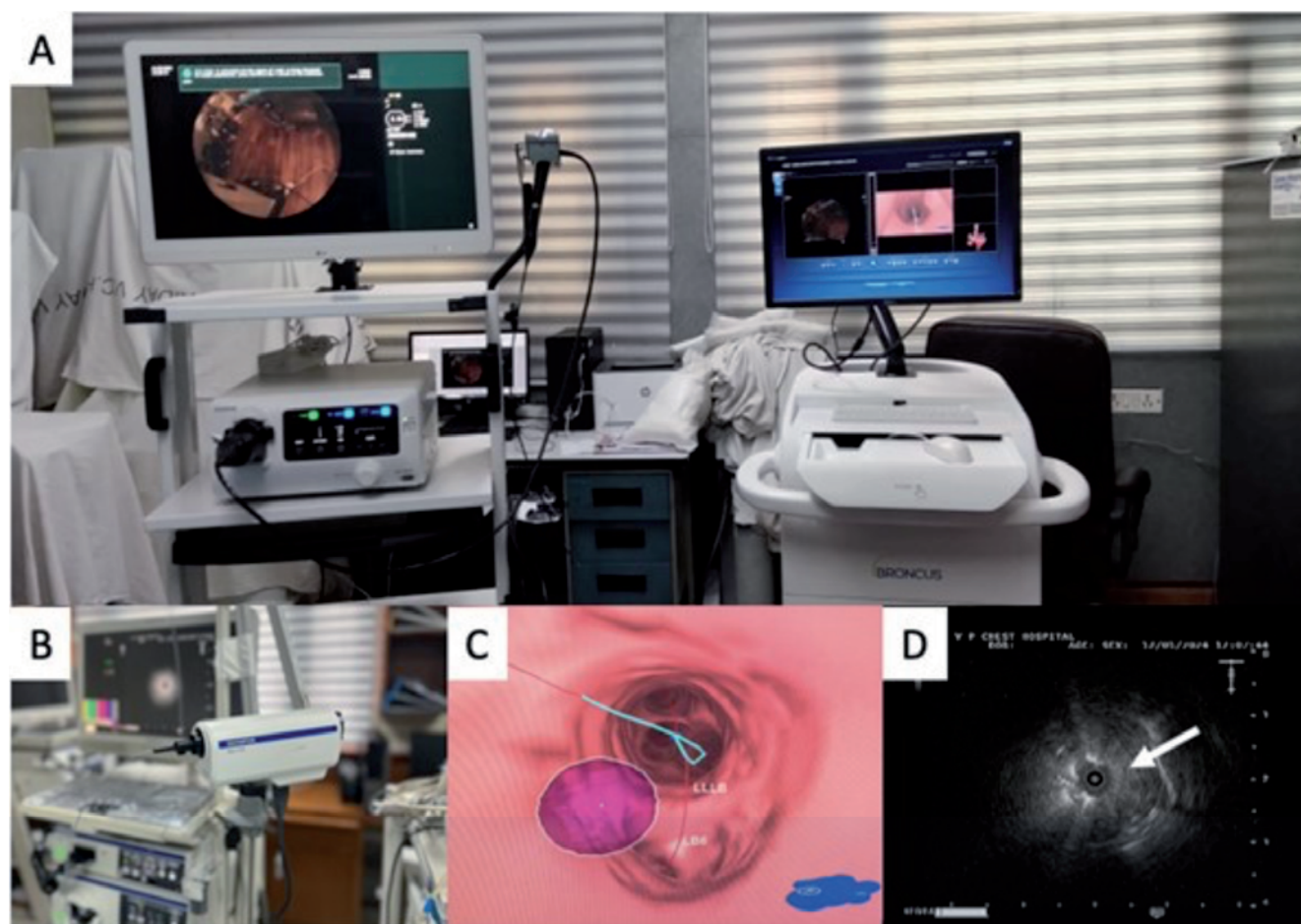


Figure 1. A) Virtual bronchoscopic navigation and bronchoscope set-up; B) radial endobronchial ultrasound (R-EBUS) probe; C) virtual navigation guiding to the lesion (pink); D) lesion as seen on R-EBUS (arrow).

(Figure 1).

Patient characteristics, including demographic data, smoking history, and relevant medical history was recorded. Baseline pulmonary function tests were also performed to assess the patient's suitability for bronchoscopic procedures and potential risks involved.

Statistical methods

Descriptive and inferential statistics, which would include diagnostic yield analysis, comparative analysis (if applicable), and subgroup analyses based on lesion characteristics and patient demographics was done. Statistical software SPSS Version 29.0.2.0 (IBM, Armonk, NY, USA) was used.

Results

A total of 20 patients diagnosed with a PPL on CT reported to the institute over a period of 1 year. The data of five patients could not be uploaded to the VBN software as the CT was not as per the software protocol. Three patients did not give consent for the procedure,

and another three could not be taken up for the procedure because of respiratory failure and abnormal clotting profile. A total of nine patients underwent VBN-assisted R-EBUS-guided biopsy sampling.

The mean age of the patients was 57.33±13.23 standard deviation (SD) years. Table 1 shows the demographic, clinical, and functional characteristics of the patients. The ratio of forced expiratory volume in the first second to forced vital capacity averaged 0.68 (SD=0.19), which was below the normal range, suggesting the presence of airflow limitation in our patient cohort. The size of the lesion across patients averaged 3.24±1.19 SD cm, suggesting a relatively consistent size among the cases. 66.7% of the cases had lesions located in the outer regions of the lungs. There was no lobar predilection on CT. On VBN, though, the most involved lobes were the left lower lobe and right upper lobe, each accounting for 33.3% of the cases. The lingula was involved in 22.2% of the cases. 44.4% of the cases had the bronchus sign present, indicating potential endobronchial lesions (Table 2).

The diagnostic yield of VBN-guided R-EBUS for PPLs was 77.7% (95% confidence interval: 68.5-85.8%). The most frequent histopathological diagnosis found was non-small cell carcinoma

Table 1. Demographic, clinical, and functional characteristics of the patients.

Characteristics		Frequency	
Sex, n (%)	Female	4 (44.4)	
	Male	5 (55.6)	
Haemoptysis, n (%)	No	7 (77.8)	
	Yes	2 (22.2)	
Smoking, n (%)	Active	1 (11.1)	
	Ex-smoker	4 (44.4)	
	Never	4 (44.4)	
Respiratory comorbid, n (%)	COPD	4 (44.4)	
	None	5 (55.6)	
History of malignancy, n (%)	No	7 (77.8)	
	Yes	2 (22.2)	
Functional status, n (%)		Mean	Standard deviation
6MWD, n (%)		306.25	44.70
Forced expiratory volume in first second (FEV1)		1.65	0.63
FEV1%		65.22	22.37
Forced vital capacity (FVC)		2.38	0.46
FVC%		75.56	14.57
Ratio		0.68	0.19

6MWD, 6-minute walk distance; COPD, chronic obstructive pulmonary disease.

Table 2. Radiological characteristics of the lesions.

Lesion visibility on chest X-ray, n (%)	No	1 (11.1)
	Yes	8 (88.9)
Location of lesion on computed tomography (CT), n (%)	Inner	3 (33.3)
	Outer	6 (66.7)
Lobe involved on CT, n (%)	Left lower lobe	2 (22.2)
	Left upper lobe	2 (22.2)
	Multiple	1 (11.1)
	Right lower lobe	2 (22.2)
	Right upper lobe	2 (22.2)
	Lobe involved on virtual bronchoscopic navigation, n (%)	Lingula
	Left lower lobe	3 (33.3)
	Right lower lobe	1 (11.1)
	Right upper lobe	3 (33.3)
Bronchus sign, n (%)	Absent	5 (55.6)
	Present	4 (44.4)



(55.5%), and results were inconclusive in two cases (22.2%). One patient (11.1%) had metastatic disease, and one (11.1%) showed an ill-defined granuloma on histopathology. Two patients (22.2%) had bleeding during the procedure, and one (11.1%) had bronchospasm. The complications were managed conservatively.

Discussion and Conclusions

PPLs are considered lesions in the peripheral one-third of the lung, although radiographic anatomical landmarks separating central and peripheral lesion does not yet exist [17].

In case of PPLs, despite a good diagnostic yield, CT-guided transthoracic biopsy has complications like pneumothorax, haemorrhage, and others [7]. TBLB, when done with a conventional bronchoscope, has a lower risk of complications but a poor diagnostic yield. Using an ultrathin bronchoscope and coupling it with technologies like fluoroscopic guidance or VBN increases the yield and carries a low risk of complications [18]. Although fluoroscopy-guided R-EBUS has a better diagnostic yield than VBN-guided R-EBUS, the risk of complications is lower with VBN guided procedure, and additionally, no radiation exposure is involved.

The diagnostic yield of VBN-guided radial EBUS for PPLs in our study was 77.8%. This is consistent with previous studies reporting yields ranging from 67.4% to 80.4%. When comparing the yield of R-EBUS with and without VBN, the addition of VBN tends to increase the diagnostic yield. A study showed that the diagnostic yield of R-EBUS increased from 50% to 67% with the addition of VBN [19]. Factors that influence the diagnostic yield include lesion location, size, and presence of the bronchus sign on CT and the use of additional technologies such as rapid on-site evaluation. In our cohort, lesions were more frequently located in the outer lung zones (66.7%) and involved multiple lobes in some cases. There was no lobar or segmental predilection for lesions. The location is important as previous studies have highlighted that lesions located in the lower lobes yield better results due to easier access and navigation to the lesion [20]. Out of our nine cases, four (44.4%) had lesions in the upper lobes, out of which a histopathological diagnosis was possible in three cases (75%). Despite the difficult manoeuvrability due to steeper angles in the upper lobe bronchi, we believe that the yield depends on the experience of the operator, and we also used an ultrathin bronchoscope to access difficult areas. The average lesion size in our study was above the 2 cm threshold, which is associated with higher yields [10]. The bronchus sign, indicating an air bronchus communicating with the lesion, was present in 44.4% of cases, which has been linked to improved diagnostic accuracy. A subgroup analysis from a previous study showed that in the bronchus sign-positive subgroup, the diagnostic yield in VBN-assisted EBUS was significantly higher compared to groups without VBN assistance [14]. This is because the bronchus sign indicates a direct airway path to the lesion, which can be followed using VBN, thereby increasing the likelihood of obtaining a successful biopsy. VBN can also reduce the time needed to locate and biopsy lesions as it provides a pre-planned route to the lesion, thus not only increasing the efficiency but also decreasing the patient's exposure to anaesthesia and potential complications during prolonged procedures [13].

A systematic review and meta-analysis showed a lower diagnostic yield for benign lesions using VBN guidance when compared to malignant lesions [12].

Our study is limited by its small sample size and retrospective nature. Larger prospective studies are needed to further elucidate

factors influencing the diagnostic yield of VBN-guided R-EBUS. Ongoing technological advancements, such as improvements in probe design, newer guidance systems like robotic bronchoscopy (Monarch and Ion systems), electromagnetic navigation bronchoscopy, and digital tomosynthesis, may enhance the diagnostic yield and accuracy further [21-23]. VBN-guided R-EBUS TBNA is a promising diagnostic technique for PPLs, offering a high diagnostic yield with a low risk of complications. As technology advances, its role in the diagnostic algorithm for lung lesions is likely to expand, underscoring the need for ongoing research and training in this technique to maximize its potential benefits.

References

1. Faurschou P, Milman N, Dirksen A, et al. Classification of pulmonary lesions into central and peripheral with a template applied on chest X-ray. *Respir Med* 1996;90:349-52.
2. Giri M, Dai H, Puri A, et al. Advancements in navigational bronchoscopy for peripheral pulmonary lesions: a review with special focus on virtual bronchoscopic navigation. *Front Med* 2022;9:989184.
3. Khan T, Usman Y, Abdo T, et al. Diagnosis and management of peripheral lung nodule. *Ann Transl Med* 2019;7:348.
4. Sung H, Ferlay J, Siegel RL, et al. Global cancer statistics 2020: GLOBOCAN estimates of incidence and mortality worldwide for 36 cancers in 185 countries. *CA Cancer J Clin* 2021;71:209-49.
5. Singh N, Agrawal S, Jiwnani S, et al. Lung cancer in India. *J Thorac Oncol* 2021;16:1250-66.
6. Gould MK, Fletcher J, Iannettoni MD, et al. Evaluation of patients with pulmonary nodules: when is it lung cancer?: ACCP evidence-based clinical practice guidelines (2nd edition). *Chest* 2007;132:108S-30S.
7. Rivera MP, Mehta AC, Wahidi MM. Establishing the diagnosis of lung cancer: Diagnosis and management of lung cancer, 3rd ed: American College of Chest Physicians evidence-based clinical practice guidelines. *Chest* 2013;143:e142S-65S.
8. Jacomelli M, Demarzo SE, Cardoso PFG, et al. Radial-probe EBUS for the diagnosis of peripheral pulmonary lesions. *J Bras Pneumol* 2016;42:248-53.
9. Sainz Zuñiga PV, Vakil E, Molina S, et al. Sensitivity of radial endobronchial ultrasound-guided bronchoscopy for lung cancer in patients with peripheral pulmonary lesions: an updated meta-analysis. *Chest* 2020;157:994-1011.
10. Herth FJF, Eberhardt R, Becker HD, Ernst A. Endobronchial ultrasound-guided transbronchial lung biopsy in fluoroscopically invisible solitary pulmonary nodules: a prospective trial. *Chest* 2006;129:147-50.
11. Kim SH, Kim MH, Lee MK, Eom JS. Problems in the pathologic diagnosis of suspected lung cancer. *Tuberc Respir Dis* 2023;86:176-82.
12. Giri M, Puri A, Wang T, et al. Virtual bronchoscopic navigation versus non-virtual bronchoscopic navigation assisted bronchoscopy for the diagnosis of peripheral pulmonary lesions: a systematic review and meta-analysis. *Ther Adv Respir Dis* 2021;15:17534666211017048.
13. Xu C, Yuan Q, Wang Y, et al. Usefulness of virtual bronchoscopic navigation combined with endobronchial ultrasound guided transbronchial lung biopsy for solitary pulmonary nodules. *Medicine* 2019;98:e14248.



14. Ishida T, Asano F, Yamazaki K, et al. Virtual bronchoscopic navigation combined with endobronchial ultrasound to diagnose small peripheral pulmonary lesions: a randomised trial. *Thorax* 2011;66:1072-7.
15. Han Y, Kim HJ, Kong KA, et al. Diagnosis of small pulmonary lesions by transbronchial lung biopsy with radial endobronchial ultrasound and virtual bronchoscopic navigation versus CT-guided transthoracic needle biopsy: a systematic review and meta-analysis. *PloS One* 2018;13:e0191590.
16. Callister MEJ, Baldwin DR, Akram AR, et al. British Thoracic Society guidelines for the investigation and management of pulmonary nodules. *Thorax* 2015;70:ii1-54.
17. Dhillon SS, Harris K. Bronchoscopy for the diagnosis of peripheral lung lesions. *J Thorac Dis* 2017;9:S1047-58.
18. Levine MZ, Goodman S, Lentz RJ, et al. Advanced bronchoscopic technologies for biopsy of the pulmonary nodule: a 2021 review. *Diagnostics* 2021;11:2304.
19. Ganaie B, Denny N, Mills J, Munavvar M. Comparison of radial mini probe endobronchial ultrasound with and without virtual bronchoscopic navigation to sample peripheral pulmonary lesions; a retrospective analysis. *Eur Respir J* 2016;48:PA4672.
20. Tian S, Li X, Liu J, Wang X, et al. Radial endobronchial ultrasound - guided bronchoscopy for the diagnosis of peripheral pulmonary lesions: a systematic review and meta-analysis of prospective trials. *Heliyon* 2024;10:e29446.
21. Prado RMG, Cicienia J, Almeida FA. Robotic-assisted bronchoscopy: a comprehensive review of system functions and analysis of outcome data. *Diagnostics* 2024;14:399.
22. Verhoeven RLJ, Kops SEP, Wijma IN, et al. Cone-beam CT in lung biopsy: a clinical practice review on lessons learned and future perspectives. *Ann Transl Med* 2023;11:361.
23. Jain A, Sarkar A, Husnain SMN, et al. Digital tomosynthesis: review of current literature and its impact on diagnostic bronchoscopy. *Diagnostics* 2023;13:2580.

Received: 11 October 2024; Accepted: 29 November 2024; Early view: 29 January 2025.

Contributions: Parul Mrigpuri: responsibility for the content of the manuscript, including the data and analysis. Parul Mrigpuri, Sidharth Raj Yadav: full access to all the details of the study and responsibility for the integrity of the data and the accuracy of the data analysis; Parul Mrigpuri, Sidharth Raj Yadav, Divyendu Sharma, Sonam Spalgais, Vidushi Rathi, Nitin Goel, Balakrishnan Menon, Raj Kumar: study design, data analysis and interpretation. Parul Mrigpuri, Divyendu Sharma, Sidharth Raj Yadav: writing of the manuscript. All the authors have read and approved the final version of the manuscript and agreed to be accountable for all aspects of the work.

Conflict of interest: the authors declare no potential conflict of interest.

Ethics approval and consent to participate: this is a retrospective observational study of patients diagnosed with a Peripheral Pulmonary Lesion on Computed Tomography and underwent Virtual Bronchoscopic Navigation assisted Radial-Endobronchial Ultrasound guided biopsy sampling in our institute over a period of one year. The files of all registered patients with investigations, clinical details, and other relevant data with the diagnosis on file's cover are kept in record in our hospital as an institute protocol. As the study involved secondary data analysis of data obtained using record review, ethics approval was not sought. The data collected did not have any identifiers, and confidentiality was ensured.

Informed consent: not applicable.

Patient consent for publication: not applicable.

Availability of data and materials: all data collected and analyzed during this study is included in this published article.

Publisher's note: all claims expressed in this article are solely those of the authors and do not necessarily represent those of their affiliated organizations, or those of the publisher, the editors and the reviewers. Any product that may be evaluated in this article or claim that may be made by its manufacturer is not guaranteed or endorsed by the publisher.

This work is licensed under a Creative Commons Attribution-NonCommercial 4.0 International License (CC BY-NC 4.0).

