

Real-world effectiveness and safety of handheld ultrasound in pleural procedures

Musaib Alavi,¹ Waris Ali,¹ Alaeddin Sagar,² Majid Shafiq,³ Muhammad Azhar,¹ Akbar S. Ali,¹ Moiz Salahuddin¹

¹Department of Medicine, Aga Khan University, Karachi, Pakistan; ²Department of Medicine, King Faisal Specialist Hospital and Research Center, Madinah, Saudi Arabia; ³Department of Medicine, Brigham and Women's Hospital, Harvard Medical School, Boston, Massachusetts, USA

Abstract

The use of ultrasound for pleural procedures is associated with a decreased risk of complications. Handheld ultrasounds allow for easier evaluation of the pleural space. Limited data exists for the use of such devices for pleural procedures. The primary objective of our study was to assess the effectiveness and safety of handheld ultrasound for pleural procedures. We performed a prospective observational study, including all consecutive patients who underwent pleural procedures using the handheld ultrasound between September 2021 and November 2023. A total of 332 pleural procedures were attempted with handheld ultrasound, of which 329 pleural procedures (99.1%) were successfully performed. The median volume of fluid drained was 500 (interquartile range: 300-800). Thoracentesis was performed in 127 patients (38.5%), tube thoracostomy in 179 patients (54.4%), and medical thoracoscopy in 23 patients (7.0%). Exudative pleural effusions were found in 264 patients (80.0%), of which 152 (46.2%) were determined to be due to infectious etiologies. A total of 4 (1.2%) patients had a complication due to the procedure. 2 patients (0.6%) had a pneumothorax, while 2 patients (0.6%) developed a hemothorax. A total of 101 patients had either low platelets (<50×10⁹/L) or use of antiplatelet or anticoagulant drugs. 128 patients (38.8%) were on positive pressure support during the pleural procedure. Our study shows that handheld ultrasounds are effective and safe for pleural procedures, including cases with septated pleural effusions and patients on antiplatelet or anticoagulant drugs.

Key words: bleeding, complications, handheld ultrasound, pleural effusion, positive pressure ventilation.

Correspondence to: Moiz Salahuddin, Department of Medicine, Aga Khan University, Stadium Road, PO Box 3500, Karachi 74800, Pakistan. Tel.: + 92302-8026665. Fax: + 9221-34934294. E-mail: moiz_salahuddin@hotmail.com

Introduction

Pleural effusion is a common and challenging clinical problem with an estimated incidence of 1.5 million new pleural effusions annually in the United States [1,2]. The management of these effusions may entail the performance of various pleural procedures, including diagnostic thoracentesis, therapeutic thoracentesis, tube thoracostomy, and medical thoracoscopy. Depending on the institution and expertise, these interventions may be done by a pulmonologist, interventional radiologist, or thoracic surgeon. Before the era of ultrasound, these procedures were performed based on anatomic landmarks and clinical examination. The use of ultrasound has been associated with a significant decrease in risk of complications when compared with non-image-guided drainage [3-5].

In addition, ultrasonography provides real-time assessment of pleural effusion in terms of its size, shape, movement of the diaphragm, and the presence or absence of pleural thickening or nodularity [6,7]. Portable ultrasound machines have allowed for evaluating patients at the bedside without the need to transport the patient to a dedicated room. However, these machines are costly,

bulky, and storing them may be cumbersome. These factors may prohibit physicians from transporting the machine to evaluate the pleural space unless there are pre-established plans to perform a procedure. Handheld ultrasound machines have been developed to try to overcome this barrier, allowing for easier and quicker evaluation of the pleural space. As these are smaller machines, they typically come with a smaller screen size, which may hypothetically limit their use when a pleural procedure is deemed necessary. To this date, no study has evaluated the use of such devices in the management of pleural effusions and their use for pleural procedures in clinical practice.

Materials and Methods

Study setting and subjects

This was a prospective observational study performed at a single academic tertiary care hospital in Karachi, Pakistan. Our hospital has Joint Commission International Accreditation and is the major referral center of the country, with a bed capacity of 500 patients. This study was performed between the period of



September 2021 and November 2023. All consecutive patients seen by the inpatient or outpatient pulmonary service with a suspected pleural effusion based on chest radiography or computed tomography were evaluated by handheld ultrasound. The patient was included in the study if an effusion was confirmed with the handheld ultrasound and drainage of the fluid was indicated. Patients were excluded if no fluid was found or if the procedure was not deemed necessary. All procedures were done under the guidance of the handheld ultrasound. Once the effusion was identified, the entry site was marked for the point of entry, and then the pleural procedure was performed as per standard. Procedures were not done under real-time ultrasound guidance. In select patients, the proceduralist performed color Doppler with the same handheld probe to assess for vessels in the intercostal space.

Pleural procedures included diagnostic and therapeutic thoracentesis, tube thoracostomy, and medical thoracoscopy. Two experienced attending physicians with formal ultrasound training performed or directly supervised pulmonary fellows performing the ultrasound-guided pleural procedures. Under the discretion of the attending physician, some pleural interventions were performed in patients with relative contraindications (on positive pressure ventilation, on antiplatelets or anticoagulation, and patients with platelets $<50 \times 10^9/L$). Patients who had a platelet count $<20 \times 10^9/L$ were transfused prior to the procedure.

Exudate effusions were diagnosed based on Light's criteria (pleural fluid protein >0.5 of serum protein, pleural fluid lactate dehydrogenase (LDH) >0.6 of serum LDH, or pleural fluid LDH $>2/3^{\text{rd}}$ of serum LDH upper limit of normal). Empyema was diagnosed based on the presence of frank pus or microbiological growth in the pleural fluid culture. Parapneumonic effusion was diagnosed if there was a neutrophilic exudative pleural fluid analysis in the absence of frank pus or microbiological growth. Tube thoracostomy was performed in a parapneumonic effusion if it was found to be a complicated parapneumonic effusion (glucose <40 mg/dL, LDH >1000 IU/L, pH <7.20) or if the parapneumonic effusion size was found to be greater than 500 mL on chest ultrasound findings. Pleural tuberculosis was diagnosed if there was a lymphocytic exudative effusion, with a high adenosine deaminase level, or a pleural biopsy with *Mycobacterium Tuberculosis* polymerase chain reaction positivity. Informed consent was waived for this study. The study protocol and informed consent waiver were approved by the Institutional Review Board of the university (2023-8600-24701).

We used a handheld ultrasound device (C4PL, Sonostar, Guangzhou, China) for all the pulmonary procedures and chest ultrasounds (Figure 1). This device projects the ultrasound images wirelessly to any smartphone or tablet. The device itself is the size of an average smartphone, measuring 160×65 mm, with a curvilinear and linear probe with Doppler. The handheld ultrasound findings were written in the medical record; however, the images were not saved in the medical record. The primary objective of our study was to assess the effectiveness and safety of using a handheld ultrasound for pleural procedures. Our secondary objectives were to evaluate the safety of performing pleural procedures using the handheld ultrasound in patients with a potentially higher risk of complications, such as patients on positive pressure ventilation or antiplatelet agents.

Statistical analysis

Data were collected on Microsoft Excel (Microsoft Office 16). IBM SPSS version 26.0 (IBM Corp.) was used for statistical analysis. Chi-squared test was used to analyze the difference in complica-

tion rates in patients who were on anticoagulants or positive pressure ventilation in comparison to those who were not.

Results

Over the span of 2 years, we performed a total of 549 chest ultrasounds for the evaluation of pleural effusion. A total of 217 patients did not undergo a pleural procedure. Of them, 204 patients had either no effusion or had a minimal effusion that was not amenable to an intervention, and 13 patients had a highly loculated effusion on ultrasound evaluation, warranting management *via* video-assisted thoracoscopic surgery (VATS). A total of 332 pleural procedures were attempted, of which 329 procedures had successful aspiration of pleural fluid, while 3 patients had an unsuccessful drainage. Of the 3 patients, 2 had large-bore chest tubes placed for empyema without any drainage, and 1 had a dry tap performed. The remainder 329 patients underwent successful pleural procedures using the handheld ultrasound guidance, and no patient required the subsequent use of a conventional ultrasound machine during the procedure or subse-

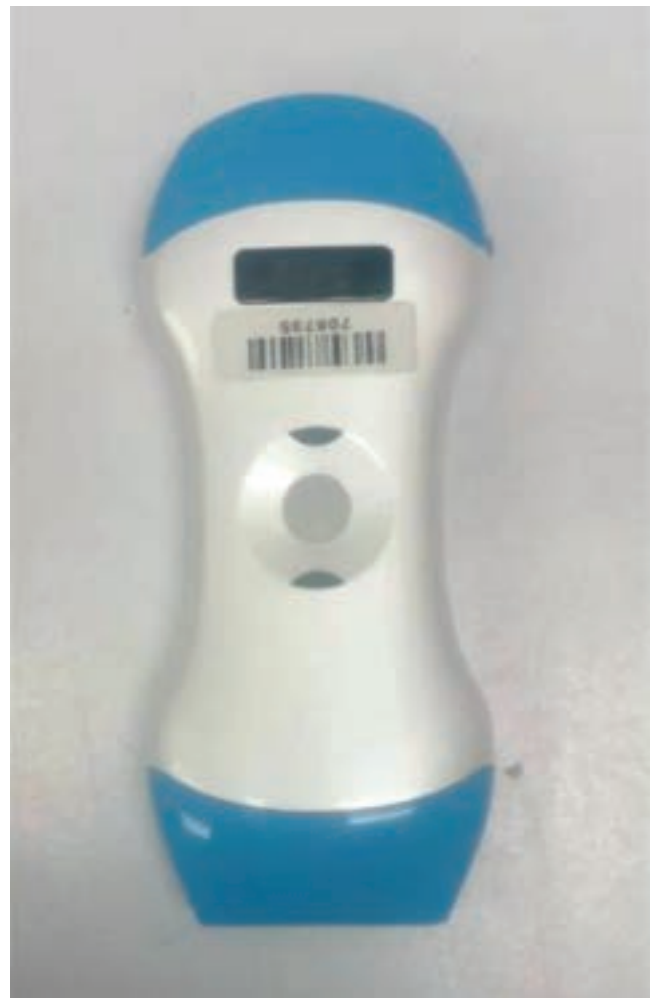

Figure 1. Image of the handheld ultrasound that was used for the pleural procedures. It connects wirelessly to a smartphone or tablet.

quently after the procedure. All thoracenteses and tube thoracostomies were performed at the patients' bedside. No indwelling pleural catheters were placed in this study. VATS was performed in 22 (6.7%) patients after the initial pleural procedure. When using the finder needle, successful aspiration of pleural fluid on the first attempt was achieved in 299 patients (90.6%). The median volume of fluid drained was 500 mL (interquartile range 300-800). Further details are listed in Table 1.

Procedure and pleural fluid characteristics

Thoracentesis was performed in 127 patients (38.5%), while a tube thoracostomy was done in 179 patients (54.4%). A 12-French small-bore chest tube was the most frequently placed tube, in 95 patients (53.0% of all tubes). Medical thoracoscopy was performed in 23 patients (7.0%). Of the 329 pleural effusions, 264 (80.0%) were found to be exudative pleural effusions. Further details are listed in Table 2.

Safety and complications

A total of 4 (1.2%) patients had a complication after their procedure: 2 (0.6%) developed a pneumothorax, and 2 (0.6%) developed a hemothorax. There was no mortality due to the complications. None of these patients developed worsening respiratory failure, and they did not require escalation of care. Of the 2 pneumothorax patients, 1 was observed without intervention, and the other patient received a needle aspiration only. Neither patient required a chest tube for the pneumothorax. Both hemothoraces were due to venous bleeds as they accumulated within 24-48 hours after the primary pleural procedure. They were diagnosed with chest X-ray imaging and a pleural fluid: serum hematocrit ratio >50%. Both hemothorax patients received a chest tube post-procedure and did not require further intervention. Both patients who had a hemothorax were on antiplatelet drugs and on positive pressure ventilation. Hemothorax was more likely in patients who were on antiplatelet drugs (4.0% vs. 0%), compared to those who were not ($\chi^2=11.2$, $p=0.02$).

Out of the 329 pleural procedures, 101 patients had a relative contraindication due to a bleeding risk. Of these, 50 patients (15.2%) were on antiplatelet agents, 37 (11.2%) were on anticoagulants, and the platelet count was less than $50 \times 10^9/L$ in 14 patients (4.3%).

Overall, 127 patients (38.6%) were on positive pressure support during the pleural procedure. Out of those, 101 (30.7%) were on non-invasive ventilation and 26 (7.9%) were on mechanical ventilation. Both pneumothorax complications occurred in patients receiving non-invasive ventilation ($\chi^2=3.2$, $p=0.15$). Further details are listed in Table 2.

Parapneumonic effusions and empyema

A total of 264 patients (80.0%) were diagnosed with exudative pleural effusions. Out of those, 152 (46.2%) were determined to be due to infectious etiologies. Microbiological cultures yielded growth in 39 cases (11.8%). There was a total of 53 (16.1%) empyemas, of which 48 (90.5%) received chest tubes. One of them had VATS performed after the thoracentesis, and 4 of the remaining empyemas were small collections, managed with therapeutic thoracentesis and antibiotics alone. Parapneumonic effusion was diagnosed in 70 patients (21.3%), of whom 49 (70.0%) received chest tubes. Tuberculous pleural effusion was found in 29 (8.8%) patients, of whom 8 (33.3%) received chest tubes. VATS was performed in 12 out of 53 (22.6%) empyema patients, and in 3 patients with parapneumonic effusion (4.3%). Further details of the etiologies of pleural effusions are shown in Figure 2.

Table 1. Baseline characteristics of the study population.

Patient characteristics	n (%)
Age	58.4±17.1 years
Gender (male)	190 (57.6)
Comorbidities	
Hypertension	177 (53.8)
Diabetes	119 (36.2)
Cardiac dysfunction	52 (15.8)
Malignancy	76 (23.1)
End-stage renal disease	35 (10.6)
Cirrhosis	21 (6.4)
Platelet count ranges ($\times 10^9/L$)	
>150	282 (85.7)
100-149	16 (4.8)
50-99	17 (5.2)
20-49	6 (1.8)
<20	8 (2.4)
Use of antiplatelet agent	50 (15.2)
Aspirin	8 (2.4)
Clopidogrel	34 (10.3)
Aspirin and clopidogrel	8 (2.4)
Use of an anticoagulant	37 (11.2)
Direct oral anticoagulant	17 (5.1)
Unfractionated heparin or therapeutic enoxaparin	18 (5.4)
Warfarin	2 (0.6)

Table 2. Pleural interventions performed.

Procedural data	n (%)
Pleural procedures successfully performed	329/332 (99.1)
Complications	4 (1.2)
Hemothorax	2 (0.6)
Pneumothorax	2 (0.6)
Pleural procedure site - right	196 (59.4)
Successful aspiration of fluid on the 1 st aspirate	299(90.6)
Fluid drained in initial aspirate (median)	500 mL (interquartile range 300-800)
Exudative pleural effusion	264 (80.0)
Pus on initial aspirate	41 (12.4)
Septated effusion on ultrasound	73 (22.1)
Thoracentesis	127 (38.5)
Medical thoracoscopy	23 (7.0)
Tube thoracostomy	179
8 French small-bore chest tube	2 (1.1)
10 French small-bore chest tube	72 (40.2)
12 French small-bore chest tube	95 (53.0)
Large bore >20 French chest tube	10 (5.6)
Procedures performed on platelets $<50 \times 10^9/L$	
Thoracentesis	6 (1.8)
Small-bore chest tube	8 (2.4)
Procedures performed on antiplatelet drugs	
Thoracentesis	29 (8.8)
Small-bore chest tube	21 (6.4)
Procedures performed on therapeutic anticoagulation	
Thoracentesis	25 (7.6)
Small-bore chest tube	12 (3.6)
Procedures performed on positive-pressure ventilation	
Thoracentesis	40 (12.2)
Small-bore chest tube	87 (26.4)



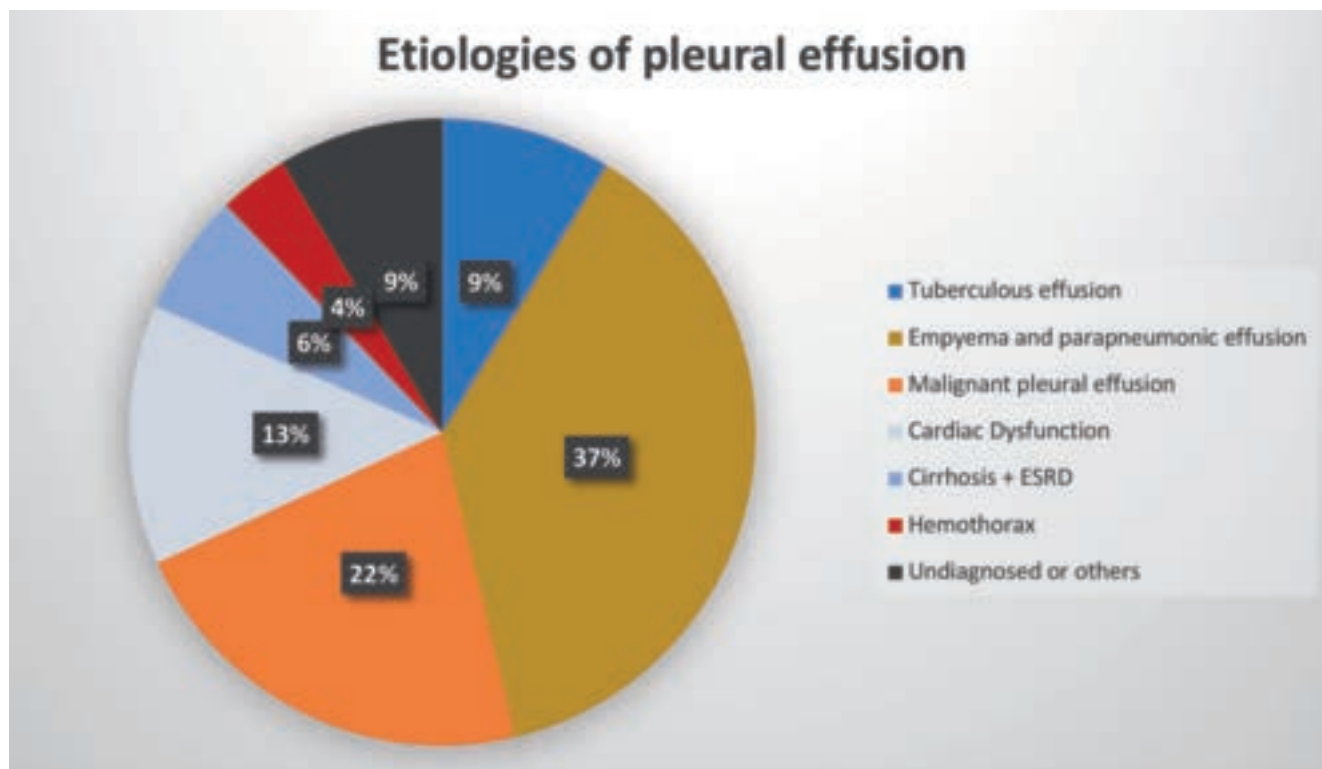


Figure 2. A pie chart depicting different etiologies of pleural effusions that were drained under handheld ultrasound guidance. Of the 72 malignant pleural effusions, 12 were due to hematological malignancies and 60 were due to solid organ malignancies. There were 12 tube thoracostomies done for hemothoraces, 5 were hemothoraces due to trauma, and 7 were spontaneous hemothoraces due to malignancy and/or anticoagulation. All patients with end-stage renal disease were on hemodialysis. ESRD, end-stage renal disease.

Discussion

Our study is the largest cohort to date of patients undergoing pleural procedures with handheld ultrasound guidance. Handheld ultrasound machines may have the potential advantage of being easier to move around, with a simpler user interface, and may be less intimidating to patients when compared to conventional portable ultrasound machines. These devices require a smaller capital investment. Most of our patients had exudative effusions, along with many patients being on antiplatelets, anticoagulants, or on positive pressure ventilation. Therefore, our real-world study suggests that pleural procedures can be performed safely and effectively using a handheld ultrasound device.

Prior studies report a complication rate of approximately 0.01-6.0% for pneumothorax using conventional ultrasound machines [3-5,8,9]. Our rates for complications are on the lower spectrum when compared to prior studies, with a pneumothorax rate of 0.6%. Our hemothorax risk was 0.6%, and prior studies report a similar bleeding risk of 0.1-1% [9,10]. It should be noted that our cohort included patients at a relatively higher risk of bleeding complications, including patients with platelet count <50k, as well as patients on antiplatelets and anticoagulants. Despite this, the overall bleeding rate was low at 0.6%. Dangers *et al.* found that the bleeding complication rate for patients on antiplatelet drugs was 3.2% [11]. The incidence of bleeding complications in patients on antiplatelet drugs in our study was 4.0%.

Dammert *et al.* reported no bleeding complications in patients who underwent small-bore chest tubes in patients on clopidogrel [12]. We recommend that every patient be individually assessed for the urgency of needing a pleural procedure. If a patient has significant respiratory compromise needing drainage or needs a timely diagnosis, then pleural procedures should not be delayed. Our study shows acceptable safety of handheld ultrasound for performing pleural procedures in patients with low platelets or use of antiplatelet or anticoagulant drugs.

We performed 128 (38.8%) of our pleural procedures in patients receiving positive pressure ventilation, with the majority being on non-invasive ventilation (102 patients). The overall pneumothorax rate was 0.6%. Both pneumothoraces occurred while the patients were on non-invasive mechanical ventilation. Therefore, the pneumothorax rate with pleural procedures on positive pressure ventilation was 1.6% in our study ($p=0.15$). Prior data show that the risk of pneumothorax with thoracentesis may be increased when patients are on mechanical ventilation [8]. However, our findings suggest that the pneumothorax risk remains small and can be safely performed with appropriate risk-benefit evaluation for the patient. It is difficult to discern whether being on NIV was the sole reason for the development of pneumothorax in these cases. Another potential contributing factor may be the difficulty in positioning due to their respiratory status, which may have made the procedure more challenging.

Our study used the Sonostar handheld ultrasound and did not



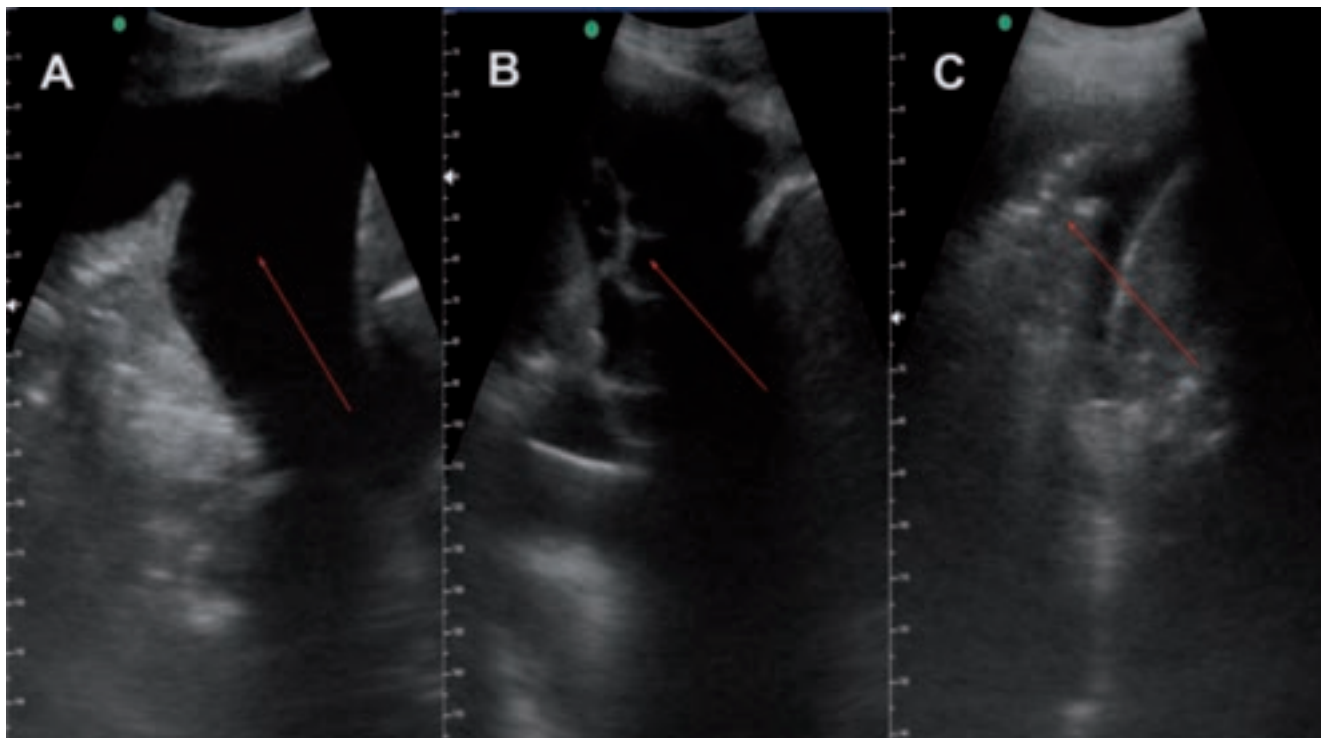


Figure 3. A) Image from the handheld ultrasound showing a simple moderate-sized pleural effusion with underlying lung atelectasis. Thoracentesis was performed for this pleural effusion; B) image from the handheld ultrasound showing a complicated pleural effusion with multiple septations. A small-bore chest tube was placed for this effusion; C) image from the handheld ultrasound showing a small pleural effusion with predominantly consolidated lung. No pleural procedure was performed on this effusion.

compare different handheld ultrasounds; therefore, we cannot generalize these findings to all handheld ultrasounds. However, in clinical practice, we have used the Butterfly and Phillips Lumify handheld ultrasound. In our experience, most handheld ultrasounds would provide similar image quality, and results should be replicable in a similar setting. Handheld ultrasound costs vary between \$2500-8000 USD, depending on the brand. Most portable ultrasounds range between \$10,000 to 40,000 USD; therefore, they are much more costly than handheld ultrasounds. Handheld ultrasounds can be used for diagnostic purposes, with studies showing appropriate views for pleural ultrasound [13,14]. Newhouse *et al.* found that handheld ultrasounds provide marginally lower image quality compared to portable ultrasound, and a safe site was found in 96.3% of patients with the handheld ultrasound [15]. Compared to portable ultrasounds, handheld ultrasounds are easier to transport, especially in large hospitals, to perform bedside procedures, and may provide similar efficacy and image quality at a significantly lower cost [16]. Figure 3 shows images obtained from the handheld ultrasound in various pleural pathologies. Our study has some limitations. Firstly, our study was a single-center study, which reduces the generalizability of these findings to all users. Secondly, due to resource limitations, we could not have a comparison arm, as we did not have consistent access to a standard portable ultrasound machine. However, the use of the portable ultrasound machine was not part of our study. Thirdly, we performed all these procedures at the bedside, which may differ from the conventional practice of performing in a procedure suite.

Conclusions

Our study suggests that handheld ultrasounds can be effectively and safely used for pleural procedures, including those with septated pleural effusions, patients on positive pressure ventilation, and patients with relative bleeding contraindications. Further studies are needed to compare handheld ultrasounds to portable ultrasounds and to compare different handheld ultrasounds.

References

1. Light RW. Pleural effusions. *Med Clin North Am* 2011;95:1055-70.
2. Taghizadeh N, Fortin M, Tremblay A. US Hospitalizations for malignant pleural effusions: data from the 2012 national inpatient sample. *Chest* 2017;151:845-54.
3. Jones PW, Moyers JP, Rogers JT, et al. Ultrasound-guided thoracentesis: is it a safer method? *Chest* 2003;123:418-23.
4. Cavanna L, Mordenti P, Berte R, et al. Ultrasound guidance reduces pneumothorax rate and improves safety of thoracentesis in malignant pleural effusion: report on 445 consecutive patients with advanced cancer. *World J Surg Oncol* 2014;12:139.
5. Barnes TW, Morgenthaler TI, Olson EJ, et al. Sonographically guided thoracentesis and rate of pneumothorax. *J Clin Ultrasound* 2005;33:442-6.
6. Muruganandan S, Azzopardi M, Thomas R, et al. The pleural effusion and symptom evaluation (PLEASE) study of breath-



- lessness in patients with a symptomatic pleural effusion. *Eur Respir J* 2020;55:1900980.
7. Qureshi NR, Rahman NM, Gleeson FV. Thoracic ultrasound in the diagnosis of malignant pleural effusion. *Thorax* 2009;64:139-43.
 8. Gordon CE, Feller-Kopman D, Balk EM, Smetana GW. Pneumothorax following thoracentesis: a systematic review and meta-analysis. *Arch Intern Med* 2010;170:332-9.
 9. Ault MJ, Rosen BT, Scher J, et al. Thoracentesis outcomes: a 12-year experience. *Thorax* 2015;70:127-32.
 10. Cantey EP, Walter JM, Corbridge T, Barsuk JH. Complications of thoracentesis: incidence, risk factors, and strategies for prevention. *Curr Opin Pulm Med* 2016;22:378-85.
 11. Dangers L, Giovannelli J, Mangiapan G, et al. Antiplatelet drugs and risk of bleeding after bedside pleural procedures: a national multicenter cohort study. *Chest* 2021;159:1621-9.
 12. Dammert P, Pratter M, Boujaoude Z. Safety of ultrasound-guided small-bore chest tube insertion in patients on clopidogrel. *J Bronchology Interv Pulmonol* 2013;20:16-20.
 13. Henning RJ. Handheld ultrasound as an adjunct to physical examination in the diagnosis of cardiopulmonary disease. *Future Cardiol* 2022;18:585-600.
 14. Moore CL, Wang J, Battisti AJ, et al. Interobserver agreement and correlation of an automated algorithm for B-line identification and quantification with expert sonologist review in a handheld ultrasound device. *J Ultrasound Med* 2022;41:2487-95.
 15. Newhouse SM, Effing TW, Dougherty BD, et al. Is Bigger really better? Comparison of ultraportable handheld ultrasound with standard point-of-care ultrasound for evaluating safe site identification and image quality prior to pleurocentesis. *Respiration* 2020;99:325-32.
 16. Haji-Hassan M, Lenghel LM, Bolboaca SD. Hand-held ultrasound of the lung: a systematic review. *Diagnostics* 2021;11:1381.

Received: 15 March 2024; Accepted: 30 August 2024; Early view: 3 October 2024.

Contributions: Musaib Alavi: study design, data collection, manuscript writing, manuscript editing, final approval of the manuscript. Waris Ali: data collection, manuscript editing, final approval of the manuscript. Alaeddin Sagar, Majid Shafiq: study design, manuscript writing, manuscript editing, final approval of the manuscript. Muhammad Azhar: data collection, manuscript editing, final approval of the manuscript. Akbar S. Ali: study design, data analysis, manuscript writing, final approval of the manuscript. Moiz Salahuddin: study design, data collection, data analysis, manuscript writing, manuscript editing, final approval of the manuscript. The manuscript has been read and approved by all the authors, the requirements for authorship as stated below in this document have been met, and each author agrees to be accountable for all aspects of the work. Moiz Salahuddin takes responsibility for the integrity of the work, from inception to published article, and should be designated as a 'guarantor'.

Conflict of interest: MSh is a Member Advisory Board for Ambu A/S. The rest of the authors have no financial disclosures.

Ethics approval and consent to participate: ethics approval and consent to participate: Informed consent was waived for this study. The study protocol and informed consent waiver were approved by the Institutional Review Board of Aga Khan University (2023-8600-24701).

Informed consent: informed consent was waived for this study.

Patient consent for publication: not applicable.

Availability of data and materials: data and materials are available from the corresponding author upon request.

Publisher's note: all claims expressed in this article are solely those of the authors and do not necessarily represent those of their affiliated organizations, or those of the publisher, the editors and the reviewers. Any product that may be evaluated in this article or claim that may be made by its manufacturer is not guaranteed or endorsed by the publisher.

This work is licensed under a Creative Commons Attribution-NonCommercial 4.0 International License (CC BY-NC 4.0).

