



Monaldi Archives for Chest Disease

eISSN 2532-5264

<https://www.monaldi-archives.org/>

Publisher's Disclaimer. E-publishing ahead of print is increasingly important for the rapid dissemination of science. The **Early Access** service lets users access peer-reviewed articles well before print / regular issue publication, significantly reducing the time it takes for critical findings to reach the research community.

These articles are searchable and citable by their DOI (Digital Object Identifier).

The **Monaldi Archives for Chest Disease** is, therefore, e-publishing PDF files of an early version of manuscripts that have undergone a regular peer review and have been accepted for publication, but have not been through the typesetting, pagination and proofreading processes, which may lead to differences between this version and the final one.

The final version of the manuscript will then appear in a regular issue of the journal.

E-publishing of this PDF file has been approved by the authors.

All legal disclaimers applicable to the journal apply to this production process as well.

Monaldi Arch Chest Dis 2023 [Online ahead of print]

To cite this Article:

Stirpe E, Bardaro F, Köhl J. **Pleural effusion and Waldenström macroglobulinemia: if cytology and flow cytometric findings do not match. A case report.** *Monaldi Arch Chest Dis* doi: 10.4081/monaldi.2023.2693

 ©The Author(s), 2023
Licensee [PAGEPress](#), Italy

Note: The publisher is not responsible for the content or functionality of any supporting information supplied by the authors. Any queries should be directed to the corresponding author for the article.

All claims expressed in this article are solely those of the authors and do not necessarily represent those of their affiliated organizations, or those of the publisher, the editors and the reviewers. Any product that may be evaluated in this article or claim that may be made by its manufacturer is not guaranteed or endorsed by the publisher.



Pleural effusion and Waldenström macroglobulinemia: if cytology and flow cytometric findings do not match. A case report

Emanuele Stirpe, Floriana Bardaro, Johanna Köhl

Department of Respiratory Diseases, Bolzano Hospital, Italy

Corresponding author: Dr Emanuele Stirpe, Pneumologia Ospedale di Bolzano, via Lorenz Böhler 5, 39100 Bolzano, Italy. Tel. +39.047.1908317. E-mail: emanuele.stirpe@sabes.it

<https://orcid.org/0000-0001-5062-4733>

Financial support & sponsorship: None.

Conflict of Interest: the authors declare that there are no conflicts of interest.

Contributions: ES in designing and writing the paper; FB and JK involved in research of scientific literature and writing the paper.

Statement of Ethics: the patient gave written informed consent to publish his case information and details.

Abstract

Pleural effusion is a rare complication of lymphoplasmacytic lymphoma. When it occurs, traditional investigation techniques may not always be successful. The flow cytometry is a fast and precise diagnostic technique, which can be helpful in the diagnosis of pleural localization of hematological diseases. We present a case report of a pleural localization of Waldenström macroglobulinaemia detected by flow cytometry.

Key words: pleural effusion; Waldenström macroglobulinaemia; flow cytometry.

Case Report

A 79-year-old man suffering by Waldenström macroglobulinemia (WM) was recovered in hospital because of fever, vomiting and diarrhoea for about three days. His medical

history included arterial hypertension, third-degree atrioventricular block (permanent pacemaker since 2019 implanted). Chest X-ray at the Emergency Room showed a pulmonary infiltration at the right basis (Figure 1A). The blood analysis revealed signs of hypochromic anemia (Hb 8.7 mg/dL, MCH 25.3 pg), C-reactive protein 9.42 mg/dL, WBC in normal range. After two weeks the patient developed a bilateral pleural effusion (Figure 1B), fever, and an increase of CRP. The patient was referred to our practice to perform a pneumological examination in the suspicion of pulmonary/pleural infection. The chest ultrasound showed bilateral pleural effusion occupying about three intercostal spaces. We performed a right diagnostic and therapeutic thoracentesis with drainage of 1400 mL of fluid. Microbiological tests were negative. The cytological examination showed regular mesothelial isolated cells, histiocytes and granulocytes. Pleural fluid resulted as a transudate with mononuclear cells 214/ μ L (protein 2 g/dL, pleural fluid/serum protein ratio 0.32, pleural fluid/serum LDH ratio 0.54, serum LDH 185/UI, fluid LDH 100/UI). We also sent a sample of pleural fluid to the laboratory of Hematology to perform an immunophenotyping with monoclonal antibodies. The results showed CD45+/CD19+/Smlg-kappa+: 0.00%, CD45+/CD19+/Smlg-lambda+: 0.00%, CD45+/CD19+/Cylg-kappa+: 10.24%, CD45+/CD19+/Cylg-lambda+: 0.00%, CD45+/CD5+: 14.11%, numerous erythrocytes and nucleated cells, of which approximately 62% were monocytes/macrophages, 30% lymphocytes, 6% neutrophils and 2% mesenchymal cells. Flow cytometry showed about 10% monoclonal B cells. In conclusion the findings were compatible with malignant pleural effusion by the known lymphoplasmacytic lymphoma.

Discussion

WM is a low-grade B-cell lymphoproliferative disorder characterized by bone marrow infiltration by lymphoplasmacytic cells associated with a monoclonal immunoglobulin M protein in the serum. The typical clinical features of WM are anemia, thrombocytopenia, hepatosplenomegaly, lymphadenopathy, and rarely hyperviscosity. Pulmonary and pleural involvement due to WM is rather rare, only occurring in 3-5% in all extramedullary cases [1]. Extramedullary WM is characterized by the presence of clonal lymphoplasmacytic infiltrate in distant sites from the bone marrow or contiguous soft tissue in a patient with known WM, excluding splenic/liver and nodal involvement

and circulating tumor cells. Banwait *et al.* described a longitudinal cohort of 985 patients with WM. Many of these cases showed involvement in specific organs such as lung, soft tissue, central nervous system, and gut. According to the authors, it could suggest possible specific tropism of the clonal cells to those organs. Pulmonary involvement was found in 13 patients (1.32%). In those 13 patients, the median time to the extramedullary pulmonary presentation was six years after diagnosis and 10/13 patients had pleural effusions [2]. Extramedullary involvement in WM also appears more prevalent among patients with advanced disease or in those previously treated. This may be due to the selection of a clone with extramedullary preference in reaction to therapeutic influence. In agreement with the thesis Banwait *et al.* and Gustine *et al.* assumed that this clonal evolution could explain the incidence of pleural effusions described in nine patients with WM, as it occurred after multiple therapies and about ten years after the initial diagnosis [2,3].

Although our patient had fever and increased inflammation markers, the origin of the pleural effusion was not clear. The etiology of idiopathic lymphocytic pleural effusion involves numerous conditions, including neoplastic and non-neoplastic diseases. Pleural biopsy can be useful but may be non-diagnostic in a significant number of cases, if there is no pleural involvement or due to sampling errors [4].

Cytological examination is the most used method to study cells in the pleural fluid; however, it might be very difficult to recognize and distinguish abnormal plasma cells in pleural fluid due to varying morphology, particularly, in the pauci-cellular samples [5]. In this case, flow cytometry could be helpful in determining whether the known WM was the underlying cause of the pleural effusion. Because of the limited number of malignant plasma cells and their potential in vitro degeneration, diagnosis may fail in patients undergoing pleural effusion puncture examination [6]. In our case the cytological examination of pleural fluid was negative, also because the pleural fluid was poor of cells, and they did not show malignancy characteristics. Immunophenotyping is a technique coupling specific antibodies to fluorescent compounds to measure specific protein expression within a cell population. The protein expression is used to identify and categorize the tagged cells. The ability of flow cytometry to determine the presence or absence of cell-surface markers serves as the basis of immunophenotyping [7]. Flow cytometry is widely used in the diagnosis, identification, disease monitoring, evaluation

of efficacy, and prognosis in various fields, such as hematology, immunology, oncology, and genetics. Flow cytometry gained increasing importance in the diagnosis, and prognostication of hematological diseases. However, it is not widely used in the diagnosis of pleural effusion. Flow cytometry is a potentially useful diagnostic tool for clinical practice. Its advantages include the possibility to distinguish between normal, reactive, and malignant plasma cells. It can be used in the evaluation of body fluids such as pleural fluid, too [8]. Flow cytometry immunophenotyping can separate the reactive cells from the malignant due their aberrant antigen expression. Neoplastic plasma cells display aberrant phenotypes and restricted immunoglobulin light chain expression at the cytoplasmic and sometimes at the surface membrane level. The aberrant plasma cell phenotype includes underexpression of markers like CD19, CD38, CD45, CD27, CD81 and overexpression of CD56, CD20, CD117, CD28 and CD200 [5].

Conclusions

Pleural effusion is a rare complication of WM. Flow cytometry is fast and accurate, and it has objective characteristics in the identification and analysis of cells. In addition, flow cytometry can be used as an adjunct diagnostic technique when the pleural localization of hematological disease is suspected.

In conclusion, this case demonstrated that flow cytometry is therefore a useful complement to traditional diagnostic methods of pleural effusion.

References

1. Gertz MA. Waldenström macroglobulinemia: 2019 update on diagnosis, risk stratification, and management, *Am J Hematol* 2019;94:266-76.
2. Banwait R, Aljawai Y, Cappuccio J, McDiarmid S et al. Extramedullary Waldenström macroglobulinemia. *Am J Hematol* 2015;90:100-4.
3. Gustine JN, Meid K, Hunter ZR, Xu L, et al. MYD88 mutations can be used to identify malignant pleural effusions in Waldenström macroglobulinaemia. *Br J Haematol* 2018;180:578-81.
4. Mansoor A, Wagner RP, DePalma L. Waldenstrom macroglobulinemia presenting as a pleural effusion. *Arch Pathol Lab Med* 2000;124:891-3.
5. Arora P, Gupta SK, Mallik N, et al. Flow cytometry in diagnosis of myelomatous pleural effusion: a case report. *Indian J Hematol Blood Transfus* 2016;32:S138-42.

6. Chen H, Li P, Xie Y, et al. Cytology and clinical features of myelomatous pleural effusion: Three case reports and a review of the literature. *Diagn Cytopathol* 2018;46:604-9.
7. Herold NC, Mitra P. Immunophenotyping. In: StatPearls [Internet]. Treasure Island: StatPearls Publishing; 2023.
8. Keklik M, Sivgin S, Pala C, et al. Flow cytometry method as a diagnostic tool for pleural fluid involvement in a patient with multiple myeloma. *Mediterr J Hematol Infect Dis* 2012;4:e2012063.

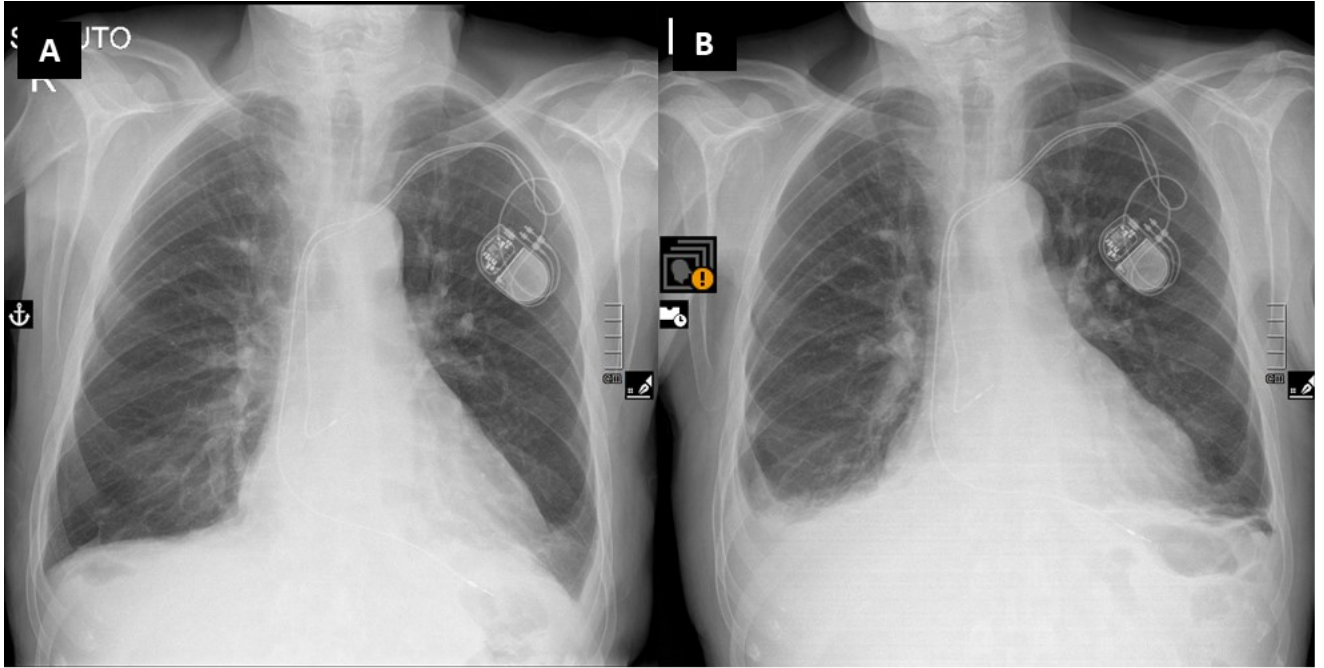


Figure 1: A) Chest X-Ray on admission. B) Chest X-Ray after 2 weeks