

A case of hoarseness of voice following COVID-19 infection

Ruby Joseph,¹ Kavitha Venkatnarayan,¹ Ashitha Nanaiah,² Priya Ramachandran¹

¹Department of Pulmonary Medicine; ²Department of Pathology, St. John's National Academy of Health Sciences, Bengaluru, India

Abstract

Mucormycosis is a fatal angio-invasive fungal infection associated with a high mortality. Apart from the traditional risk factors, COVID-19 infection and steroid therapy for the same have been recently identified to predispose to this life-threatening infection. Usual presentations of mucormycosis include rhino-orbito-cere-

bral, pulmonary, gastrointestinal, renal and cutaneous involvement. We report an unusual case of mediastinal involvement by mucormycosis in a patient recovering from moderate COVID-19 pneumonia. Early diagnosis, prompt initiation of antifungal therapy accompanied by timely surgical debridement were pivotal in averting morbidity and mortality in this patient.

Introduction

The COVID-19 pandemic triggered a rise in the cases of mucormycosis worldwide, especially in India [1]. This surge was attributed to various causes, hyperglycemia and inadvertent use of corticosteroids being the most important. COVID-19 infection shares a bidirectional relationship with diabetes mellitus. Corticosteroids used in the treatment of moderate to severe COVID-19 related hypoxemic respiratory failure further worsen the hyperglycemia and immune dysregulation associated with the infection [2]. The predominant site of involvement reported with COVID-19-associated mucormycosis is rhino-orbito-cerebral, followed by pulmonary, disseminated and gastrointestinal. Prompt initiation of antifungal therapy, surgical debridement of necrotic tissue and control of the underlying risk factor are the three pillars to managing this disease which otherwise carries a high mortality [1,3].

Case Report

A 47-yr-old gentleman, a reformed smoker with diabetes mellitus and hypertension, developed fever and myalgia for 3 days and was diagnosed with COVID-19 infection. He was initially advised home isolation and monitoring in view of mild symptoms. Over the next 3-4 days, he developed breathlessness and was hospitalized for acute hypoxemic respiratory failure in another center. He was treated with supplemental oxygen, intravenous remdesivir, intravenous ceftriaxone and steroids (dexamethasone 8 mg twice a day) for 7 days. Eventually, he improved and was discharged after 10 days of hospitalization. A week later, he started having dry cough and hoarseness of voice for which he was referred to our center for further evaluation. There was no history of fever, hemoptysis, dysphagia or stridor. On examination, he was hemodynamically stable, maintaining a saturation of 96% on room air with an unremarkable systemic examination.

Laboratory investigations were within normal limits except for leucocytosis of 14,350 cells/mm³. Blood sugars were poorly controlled with a HbA1c of 9.8%. A computed tomography (CT) scan of the thorax was performed which showed multiple necrotic mediastinal lymph nodes with circumferential thickening and partial luminal obliteration of the left main bronchus. A few peripheral based ground glass opacities were noted in the lung parenchyma which were consistent with COVID-19 infection (Figure 1). Flexible bronchoscopy showed left vocal cord palsy and a bulge at

Correspondence: Dr Kavitha Venkatnarayan, Associate Professor, Department of Pulmonary Medicine, St John's National Academy of Health Sciences, 3rd floor, Oncology Block, Sarjapur Road, Bengaluru 560034, India.
Tel. +91.9013770826.
E-mail: kavaiims@gmail.com

Key words: hoarseness; mediastinal mucormycosis; COVID associated mucormycosis.

Contributions: all the authors have contributed towards patient diagnosis and management and manuscript preparation and revision.

Conflict of interest: the authors declare that they have no competing interests, and all authors confirm accuracy.

Ethics approval and consent to participate: no ethical committee approval was required for this case report by the Department, because this article does not contain any studies with human participants or animals. Informed consent was obtained from the patient included in this study.

Consent for publication: the patient gave his written consent to use his personal data for the publication of this case report and any accompanying images.

Received: 3 November 2022.
Accepted: 27 December 2022.
Early view: 27 January 2023.

Publisher's note: all claims expressed in this article are solely those of the authors and do not necessarily represent those of their affiliated organizations, or those of the publisher, the editors and the reviewers. Any product that may be evaluated in this article or claim that may be made by its manufacturer is not guaranteed or endorsed by the publisher.

©Copyright: the Author(s), 2023
Licensee PAGEPress, Italy
Monaldi Archives for Chest Disease 2023; 93:2472
doi: 10.4081/monaldi.2023.2472

This article is distributed under the terms of the Creative Commons Attribution-NonCommercial International License (CC BY-NC 4.0) which permits any noncommercial use, distribution, and reproduction in any medium, provided the original author(s) and source are credited.

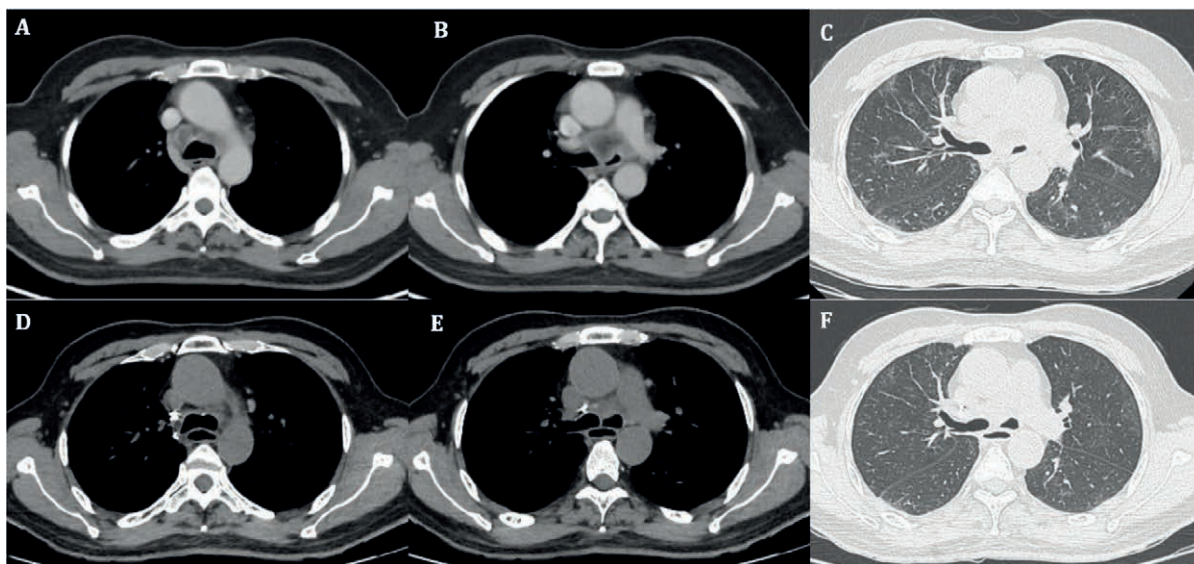


Figure 1. CT thorax (A-C) at the time of diagnosis; A,B) necrotic mediastinal lymph node enlargement in the paratracheal and pre-carinal region with compression of the left main bronchus; C) ground glass opacities in the peripheral subpleural location. CT thorax (D-F) after 6 weeks of therapy, showing near complete resolution of the lymph node enlargement and the ground glass opacities.

the carina extending into the left main bronchus with partial luminal obliteration. On further negotiation into the left main bronchus an ulcerative lesion was seen with purulent secretions at the origin of the left main bronchus. Endobronchial biopsies were obtained from the margins of this lesion and bronchial washings were taken (Figure 2). Bronchial washings were negative for bacterial cultures, acid fast bacilli and cartridge based nucleic acid amplification was negative for *Mycobacterium tuberculosis*. However, it showed aseptate fungal hyphae on potassium hydroxide calcofluor stain. Fibrinopurulent exudates with few entangled broad aseptate fungal hyphae, morphologically resembling *Mucorales* were seen on histopathological examination of the endobronchial biopsies. PAS and GMS stains ratified the above findings (Figure 3). CT scan of the paranasal sinuses showed no features suggestive of fungal sinusitis or orbital involvement.

A diagnosis of mediastinal mucormycosis with endobronchial involvement was made and liposomal amphotericin B (5 mg/kg/d) was initiated along with glycemic control measures. In view of airway luminal compromise and the potential for involvement of other mediastinal structures, a surgical debridement was planned. The case was discussed with the thoracic surgeons and since the patient was otherwise stable and operable, a mini thoracotomy with drainage of pus and subcarinal lymph node excision was performed. Lymph node aspirate was negative for acid fast bacilli and bacterial cultures, but fungal stains revealed aseptate fungal hyphae. Histopathological examination of the excised subcarinal lymph node showed fibro-collagenous tissue with necrosis, dense inflammation, occasional multinucleated giant cell and histiocytic response with broad aseptate fungal hyphal colonies suggestive of *Mucorales*. Intravenous liposomal amphotericin B was continued post-operatively till a cumulative dose of 4 grams. Patient was then switched to oral posaconazole 300 mg/d and discharged. Posaconazole was continued for 3 months and then stopped. A repeat CT thorax done after therapy, showed significant resolution of the mediastinal nodes and restoration of left main bronchus luminal patency (Figure 1 D-F). Repeat bronchoscopy showed complete resolution of endobronchial ulcers and carinal bulge. A

small pit was seen at the origin of left main bronchus which was likely post-operative (Figure 2 C,D). On the last follow up after 1 year of therapy, the patient remains asymptomatic with significant improvement in hoarseness of voice as well.

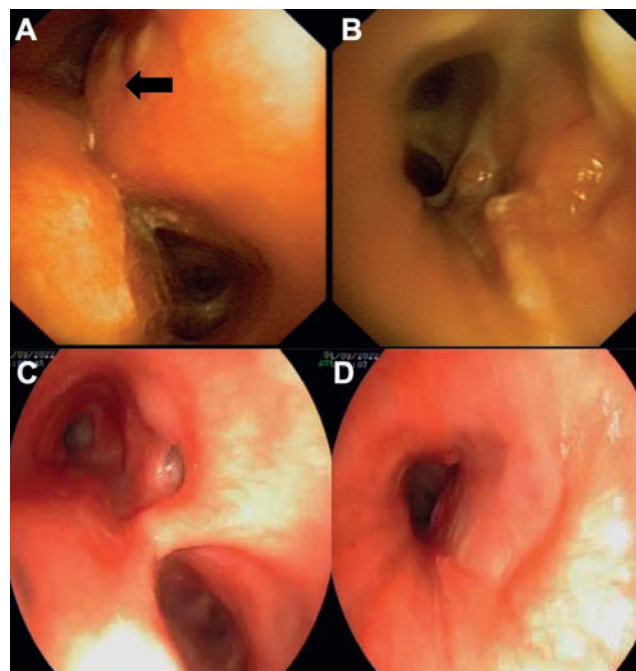


Figure 2. Bronchoscopy (A,B) at the time of diagnosis showing bulge (A) seen at the level of carina at the origin of left main bronchus (black arrow), and distal end of left main bronchus (B) showing ulcerative lesions with purulent secretions. Follow up bronchoscopy (C,D) showing resolution of carinal bulge with a bronchial pit (C), and complete resolution (D) of left main bronchus ulcerative lesions.

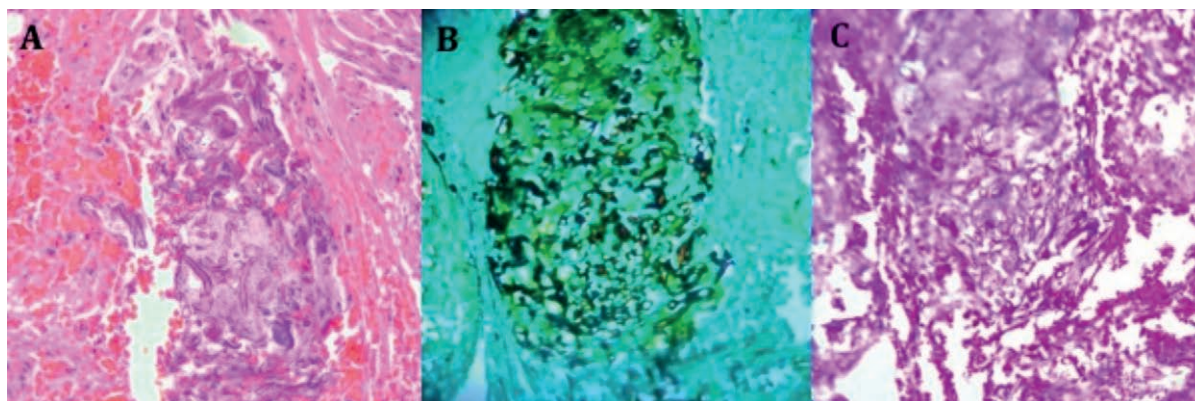


Figure 3. Endobronchial tissue biopsy. A) H&E stain (40x) shows broad aseptate fungal hyphae morphologically resembling *Mucorales*. B) GMS stain (40x) highlights the fungal organisms. C) PAS stain (40x) highlights the fungal organisms.

Discussion

Mucormycosis is a fatal angio-invasive opportunistic infection caused by ubiquitous fungus of the order *Mucorales*. Traditionally identified risk factors for mucormycosis include diabetes mellitus, hematological malignancies, neutropenia, renal failure, use of immunosuppressants and solid organ transplants. In contrast to the western countries where hematological malignancies are the major risk factors, mucormycosis in India is predominantly seen in patients with diabetes mellitus [1].

The emergence of the corona virus disease 2019 (COVID-19) pandemic compounded the situation by bringing together two major predisposing factors namely diabetes and corticosteroid use. COVID-19 shares a bidirectional relationship with diabetes. Diabetics are predisposed to increased risk of and progression to severe infection. On the other hand, the pro-inflammatory state associated with COVID-19, has direct and indirect effects on pancreatic β cells and insulin target organs leading to hyperglycemia [2]. Corticosteroids were the only drugs to show promise in the initial stages of the pandemic. However, inadvertent use of steroids combined with underlying diabetes mellitus and hyperglycemia, heightened the predisposition to develop secondary infections including fungal infections in these patients. Apart from COVID-19-associated aspergillosis, several cases of mucormycosis were reported following COVID-19 infection especially from the Indian subcontinent [3].

Although the definite pathophysiology underlying COVID-19-associated mucormycosis (CAM) remains unknown several theories have been put forth. The inflammatory state induced by hyperglycemia is augmented by antiviral immune response and the resultant pro-inflammatory milieu enhances the expression of fungal virulence factors permissive for the development of CAM. Additionally, nasal epithelial receptors promoting fungal invasion are upregulated by COVID-19 infection, presence of diabetic ketoacidosis and higher iron concentrations. This susceptibility is further increased by the accompanying lymphopenia, impaired neutrophil function secondary to the use of corticosteroids and inadvertent use of antibiotics in these patients. Animal studies have shown male predisposition to mucormycosis in the presence of diabetic ketoacidosis which was also observed in clinical practice [4,5].

Worldwide, uncontrolled diabetes and corticosteroid use were the most common predisposing conditions identified for CAM.

Rhino-orbito-cerebral mucormycosis was the most common manifestation in India with pulmonary involvement seen mainly in the intensive care setting. A high mortality rate was reported in these patients with significant morbidity in the form of vision loss amongst survivors [4]. Presence of pulmonary or disseminated mucormycosis and admission to intensive care unit were independent predictors of mortality among these patients. Combination antifungal therapy (amphotericin followed by azoles) was associated with improved survival [3].

Mediastinal involvement by mucormycosis is an unusual presentation. It is hypothesized that inhaled fungal spores reach the mediastinal lymph nodes through alveolar macrophages. Owing to the propensity for angioinvasion and tissue necrosis, the resultant mediastinal inflammation can involve the bronchi and other vital structures [6]. The earliest case was reported by Connor et al in a patient with leukemia with invasion of the myocardium, coronary and spinal arteries by mucormycosis on *postmortem* examination [7]. A systematic review of 12 cases of mediastinal mucormycosis, reported a high mortality of 89%. Most common presenting symptoms were secondary to compression on the mediastinal structures including dyspnea, hoarseness and superior vena caval obstruction. Bronchial perforations were noted in two cases [6,8].

The importance of a multi-disciplinary team including the clinician, radiologist, thoracic surgeons, microbiologist and pathologist in diagnosing and managing these patients cannot be over-emphasized. Early diagnosis, prompt initiation of antifungals and surgical debridement along with management of the underlying predisposing conditions are vital components of an optimal management strategy. The duration of antifungal therapy needs to be individualized based on the response to therapy which in turn depends on the underlying predisposing conditions, structures involved and extent of surgical debridement feasible in the given patient. The right time for surgery as well needs to be decided on a case-to-case basis, depending upon the patient's condition and the feasibility of debridement of the involved structures. A diligent pre-operative evaluation and discussion with the thoracic surgeons especially in patients with involvement of mediastinal structures is extremely crucial [9]. Apart from antifungals and surgical debridement, supportive therapy in the form of optimizing glycemic control and reversal of the underlying immunosuppression as feasible are of paramount importance. Mediastinal irrigation with antifungals may have an additional benefit of local source control [10].

Our patient presented with exclusive mediastinal symptoms

and was referred to our center with a suspicion of malignancy. Radiologically, mucormycosis presenting with isolated mediastinal lymphadenopathy is extremely rare. Hence, radiologically a possibility of fungal infection was not considered. In a recent consensus statement on COVID-19 associated pulmonary mucormycosis, 89% of the guideline group thought mediastinal adenopathy was 'not suggestive' of mucormycosis [9]. However, an early suspicion following the bronchoscopy, proper sample processing for a possible infective etiology and a prompt diagnosis helped in optimal management. The importance of a multidisciplinary team involving the microbiologist, pathologist, pulmonologist and the thoracic surgeons in diagnosis and management is evident from this case. We believe that timely surgical debridement was pivotal in averting mortality in our patient by preventing further spread to vital mediastinal structures.

References

1. Prakash H, Ghosh AK, Rudramurthy SM, et al. A prospective multicenter study on mucormycosis in India: Epidemiology, diagnosis, and treatment. *Med Mycol* 2019;57:395-402.
2. Landstra CP, de Koning EJP. COVID-19 and diabetes: Understanding the interrelationship and risks for a severe course. *Front Endocrinol* 2021;12:649525.
3. Muthu V, Rudramurthy SM, Chakrabarti A, et al. Epidemiology and pathophysiology of COVID-19-associated mucormycosis: India versus the rest of the world. *Mycopathologia* 2021;186:739-54.
4. Hoenigl M, Seidel D, Carvalho A, et al. The emergence of COVID-19 associated mucormycosis: a review of cases from 18 countries. *Lancet Microbe* 2022;3:e543-52.
5. Rudramurthy SM, Hoenigl M, Meis JF, et al. ECMM/ISHAM recommendations for clinical management of COVID-19 associated mucormycosis in low- and middle-income countries. *Mycoses* 2021;64:1028-37.
6. Dhoria S, Agarwal R, Chakrabarti A. Mediastinitis and bronchial perforations due to mucormycosis. *J Bronchol Interv Pulmonol* 2015;22:338-42.
7. Connor BA, Anderson RJ, Smith JW. Mucor mediastinitis. *Chest* 1979;75:524-6.
8. Liu HC, Jan MS, Lin YC, et al. A rare pulmonary zygomycosis manifested as chronic mediastinitis and bronchial perforation. *Eur Respir J* 2011;38:734-5.
9. Muthu V, Agarwal R, Patel A, et al. Definition, diagnosis, and management of COVID-19-associated pulmonary mucormycosis: Delphi consensus statement from the Fungal Infection Study Forum and Academy of Pulmonary Sciences, India. *Lancet Infect Dis* 2022;22:e240-53.
10. Cooper JD, Gotoff RA, Foltzer MA, et al. Mediastinal mucormycosis: Case report, review of literature and treatment with continuous liposomal amphotericin B irrigation. *Mycoses* 2019;62:739-45.